



**TURUN  
YLIOPISTO**  
UNIVERSITY  
OF TURKU

# THE CONTEMPORARY ENDOVASCULAR TREATMENT OF INTRACRANIAL ANEURYSMS

---

Kemal Alpay





**TURUN  
YLIOPISTO**  
UNIVERSITY  
OF TURKU

# **THE CONTEMPORARY ENDOVASCULAR TREATMENT OF INTRACRANIAL ANEURYSMS**

---

Kemal Alpay

## University of Turku

---

Faculty of Medicine  
Department of Clinical Medicine  
Radiology  
Doctoral programme in Clinical Research

## Supervised by

---

Professor, Riitta Parkkola  
University of Turku  
Department of Radiology  
Turku, Finland

Adjunct professor, Riitta Rautio  
University of Turku  
Department of Radiology  
Turku, Finland

## Reviewed by

---

Adjunct professor, Miikka Korja  
University of Helsinki  
Department of Neurosurgery  
Helsinki, Finland

Adjunct professor, Niko Sillanpää  
Tampere University Hospital  
Centre for Vascular and Interventional  
Radiology  
Tampere, Finland

## Opponent

---

Professor, Tommy Andersson  
Karolinska Institutet  
Department of Clinical Neuroscience  
Stockholm, Sweden

The originality of this publication has been checked in accordance with the University of Turku quality assurance system using the Turnitin OriginalityCheck service.

ISBN 978-951-29-8987-4 (PRINT)  
ISBN 978-951-29-8988-1 (PDF)  
ISSN 0355-9483 (Print)  
ISSN 2343-3213 (Online)  
Painosalama, Turku, Finland 2022

*To Aili, Olivia and Laura*

UNIVERSITY OF TURKU

Faculty of Medicine

Department of Clinical Medicine

Radiology

Kemal Alpay: The Contemporary Endovascular Treatment of Intracranial Aneurysms

Doctoral Dissertation, 131 pp.

Doctoral programme in Clinical Research

September 2022

## ABSTRACT

The first endovascular treatment of intracranial aneurysms began with simple coiling in 1991. Ever since, it has developed significantly, and endovascular treatment is now the first choice for most intracranial aneurysms. However, some intracranial aneurysms such as wide-necked, blood-blister-like, fusiform and dissecting intracranial aneurysms are not suitable for simple coiling. In 2008, intraluminal flow diversion was introduced for uncoilable saccular intracranial aneurysms of the internal carotid artery, and since then, the indications of intraluminal flow diversion have expanded to complex aneurysms like blister-like, dissecting, and fusiform intracranial aneurysms. In 2010, intrasaccular flow disruption was introduced with the Woven EndoBridge (WEB) for the treatment of naïve wide-necked bifurcation aneurysms. Several studies have shown the safety and efficacy of flow diverters and WEB in the treatment of intracranial aneurysms.

In our study the safety and efficacy of the WEB and flow diverters were assessed in Finnish population. Furthermore, we identified and analysed the factors influencing radiological outcomes after the contemporary endovascular treatments. A rate of 90% adequate radiological outcomes can be achieved in the treatment of naïve and recurrent wide-necked intracranial aneurysms with the WEB. No rupture or re-rupture observed after the WEB treatment. The flow diverters can provide a high occlusion rate for elective and acutely ruptured intracranial aneurysms. However, a 45% rate of complications was observed in flow diversion for acutely ruptured intracranial aneurysms.

The WEB for wide-necked intracranial aneurysms including wide-necked recurrent intracranial aneurysms appears to be safe and efficient, and is a valuable alternative when the conventional methods are not amenable. The aneurysm morphology and size seem to influence the radiological outcomes after the WEB treatment. Flow diverters provides high occlusion rates. However, the flow diversion of acutely ruptured intracranial aneurysms carries a high rate of complications. Flow diversion can be justified as a last-resort option when other endovascular methods are not suitable for acutely ruptured intracranial aneurysms.

**KEYWORDS:** Aneurysm, subarachnoid hemorrhage, stroke, endovascular treatment, the woven endobridge, flow diverter

TURUN YLIOPISTO

Lääketieteellinen tiedekunta

Kliininen laitos

Radiologia

Kemal Alpay: Aivovaltimoaneurysmien nykyaikainen suonensisäinen hoito

Väitöskirja, 131 s.

Turun kliininen tohtoriohjelma

Syyskuu 2022

## TIIVISTELMÄ

Aivovaltimoaneurysma hoidettiin koiliembolisaatiolla onnistuneesti ensimmäisen kerran vuonna 1991, ja siitä lähtien endovaskulaariset tekniikat ovat kehittyneet merkittävästi. Endovaskulaarinen menetelmä onkin nykyään ensisijainen valinta useimpien aneurysmien hoitoon. Koska rakkulamaiset, dissekoivat ja fusiformiset aneurysmat ovat vaikeita hoitaa tavanomaisilla endovaskulaarisilla menetelmillä, vaikeahoitoisia aneurysmia varten otettiin vuonna 2008 käyttöön flow diverter -stentit. Niiden alkuperäinen käyttöaihe oli sisemmän kaulavaltimon jättianeurysmien hoito; nyt käyttöaiheet ovat laajentuneet niin rakkulamaisten kuin dissekoivien aneurysmien hoitoon. Intrasakkulaarinen laite Woven Endobridge (WEB) kehitettiin vuonna 2010 leveäkaulaisten aivovaltimoaneurysmien hoitoon. Useat tutkimukset ovat osoittaneet sekä flow diverter -stentin sekä WEB:in turvallisuuden ja tehokkuuden aivoaneurysmien hoidossa.

Tutkimuksessa arvioitiin WEB ja flow diverter -hoidon turvallisuutta ja tehokkuutta Suomessa. Erityistä huomiota kiinnitettiin tekijöihin, jotka ennustavat radiologisia tuloksia nykyaikaisen hoidon jälkeen. Tutkimuksella todettiin, että WEB-hoidolla voidaan saavuttaa 90%:sti lähes täydellinen radiologinen hoitotulos. WEB-hoidon jälkeen aneurysmien puhkeamista ei havaittu. Flow diverter -hoidolla saavutetaan 90%:sti täydellinen tai lähes täydellinen radiologinen tulos, mutta 45%:lla potilaista esiintyy jokin flow diverter -hoitoon liittyvä komplikaatio akuutisti puhjenneiden aneurysmien hoidossa.

WEB on tehokas menetelmä sekä uusien että uusiutuneiden leveäkaulaisten aneurysmien hoidossa. Se on käyttökelpoinen silloin, kun perinteiset menetelmät eivät riitä. Aneurysman muoto ja koko vaikuttavat WEB:in hoitotuloksiin. Flow diverterit mahdollistavat hyvän radiologisen hoitotuloksen akuutisti repeytyneissä aivoaneurysmissa. Niiden flow diverter -hoitoon liittyy kuitenkin huomattavan korkea komplikaatoriski, mutta mikäli muu menetelmä ei potilaan akuutisti puhjenneen aneurysman hoitoon sovellu, sitä voidaan viimeisenä hoitomuotona perustellusti käyttää.

AVAINSANAT: Aivovaltimopullistuma, aneurysma, lukinkalvonalainen verenvuoto, suonensisäinen hoito, woven endobridge, flow diverter

# Table of Contents

<b>Abbreviations .....</b>	<b>9</b>
<b>List of Original Publications .....</b>	<b>11</b>
<b>1 Introduction .....</b>	<b>12</b>
<b>2 Review of the Literature .....</b>	<b>14</b>
2.1 Intracranial aneurysms .....	14
2.1.1 Epidemiology and risk factors.....	14
2.1.2 Common intracranial aneurysms.....	15
2.1.2.1 Saccular intracranial aneurysms .....	15
2.1.2.2 Fusiform intracranial aneurysms .....	16
2.1.2.3 Dissecting intracranial aneurysms .....	16
2.1.3 Uncommon intracranial aneurysms .....	17
2.1.3.1 Infective aneurysms.....	17
2.1.3.2 Traumatic intracranial aneurysms .....	18
2.1.3.3 Blister-like intracranial aneurysms .....	18
2.1.3.4 Pediatric intracranial aneurysms .....	19
2.2 Subarachnoid hemorrhage.....	20
2.2.1 Incidence of aneurysmal subarachnoid hemorrhage ...	20
2.3 Factors involved in aneurysm rupture.....	20
2.3.1 Patient related factors .....	20
2.3.2 Aneurysm related factors .....	21
2.4 Symptoms of aneurysmal subarachnoid hemorrhage.....	23
2.5 Diagnosis of subarachnoid hemorrhage and intracranial aneurysms .....	23
2.6 Complications of aneurysmal subarachnoid hemorrhage .....	25
2.7 Neurological outcome after aneurysmal subarachnoid hemorrhage.....	28
2.8 Treatment of intracranial aneurysms .....	30
2.8.1 The microsurgical clipping .....	31
2.8.2 The conventional endovascular treatment.....	33
2.8.2.1 The simple coiling.....	33
2.8.2.2 The balloon- and stent-assisted coiling .....	35
2.8.3 The contemporary endovascular treatment .....	37
2.8.3.1 Intraluminal flow diversion.....	37
2.8.3.2 Intrasaccular flow disruption .....	41
2.9 The follow-up of intracranial aneurysms .....	45
2.10 The assessment of radiological outcomes.....	47



<b>3</b>	<b>Aims .....</b>	<b>49</b>
<b>4</b>	<b>Materials and Methods.....</b>	<b>50</b>
4.1	Study design and patients .....	50
4.1.1	The treatment of recurrent intracranial aneurysms with the Woven EndoBridge (I) .....	50
4.1.2	The flow diversion with the new Surpass Evolve (II) ....	50
4.1.3	The treatment of acutely ruptured intracranial aneurysms with flow diverters (III) .....	51
4.1.4	The Woven Endobridge for naïve intracranial aneurysms (IV).....	51
4.2	Endovascular treatment.....	51
4.2.1	The WEB treatment (I, IV) .....	51
4.2.2	The Surpass Evolve flow diverter treatment (II) .....	52
4.2.3	The flow diverter treatment of acutely ruptured intracranial aneurysms (III) .....	52
4.3	Clinical and radiological assessments .....	53
4.3.1	The treatment of recurrent intracranial aneurysms with the Woven Endobridge (I) .....	53
4.3.2	The flow diversion with the new Surpass Evolve (II) ....	54
4.3.3	The treatment of acutely ruptured intracranial aneurysms with flow diverters (III) .....	54
4.3.4	The Woven EndovBridge for naïve intracranial aneurysms (IV).....	54
4.4	Statistical analysis .....	55
4.5	Ethical aspects .....	55
<b>5</b>	<b>Results .....</b>	<b>56</b>
5.1	The treatment of recurrent intracranial aneurysms with the Woven Endobridge (I) .....	56
5.1.1	Patient, aneurysm, and intervention characteristics ....	56
5.1.2	Radiological Outcomes.....	57
5.1.3	Complications and Clinical Outcomes .....	57
5.2	Flow diversion with the new Surpass Evolve (II).....	57
5.2.1	Patient, aneurysm, and intervention characteristics ....	57
5.2.2	Radiological outcomes .....	58
5.2.3	Complications and clinical outcomes .....	58
5.3	The treatment of acutely ruptured intracranial aneurysms with flow diverters (III) .....	58
5.3.1	Patient, aneurysm, and intervention characteristics ....	58
5.3.2	Radiological outcomes .....	58
5.3.3	Complications and clinical outcomes .....	59
5.4	The Woven EndoBridge for naïve intracranial aneurysms (IV).....	60
5.4.1	Patient, aneurysm, and intervention characteristics ....	60
5.4.2	Radiological outcomes .....	61
5.4.3	Factors affecting radiological outcome .....	62
5.4.4	Complications and clinical outcome.....	63
<b>6</b>	<b>Discussion .....</b>	<b>64</b>

6.1	The treatment of recurrent intracranial aneurysms with the Woven EndoBridge (I).....	64
6.2	Flow diversion with the new Surpass Evolve flow diverter (II).....	65
6.3	The treatment of acutely ruptured intracranial aneurysms with flow diverters (III).....	66
6.4	The Woven EndoBridge for naïve intracranial aneurysms (IV).....	68
6.5	Study limitations and strengths.....	69
6.6	Future perspectives.....	69
<b>7</b>	<b>Conclusions .....</b>	<b>71</b>
	<b>Acknowledgements.....</b>	<b>72</b>
	<b>References .....</b>	<b>74</b>
	<b>Original Publications.....</b>	<b>95</b>

# Abbreviations

ACA	anterior cerebral Artery
Acom	anterior communicating Artery
ALD	activities of daily living
aSAH	aneurysmal subarachnoid haemorrhage
BRAT	the Barrow Ruptured Aneurysm Trial
CTA	computed tomography angiography
CSF	cerebrospinal fluid
DAPT	dual anti-platelet therapy
DCI	delayed cerebral ischemia
DSA	digital subtraction angiography
EVD	external ventricular drain
FD	flow diverter
FRED	flow direction endoluminal device
FRED-JR	flow direction endoluminal device junior
GCS	Glasgow come scale score
GOS	Glasgow outcome score
H&H	Hunt&Hess scale
IADL	instrumental activities of daily living
ICG-VA	indocyanine green video angiography
ISAT	international Subarachnoid Aneurysm Trial
ISUIA	international Study of Unruptured Intracranial Aneurysms
IA	intracranial aneurysm
ICA	internal carotid artery
ICH	intra cerebral hemorrhage
IVH	intraventricular haemorrhage
LP	lumbar puncture
MCA	middle cerebral artery
MMSE	mini-mental state examination
MRA	magnetic resonance angiography
mRS	modified Rankin Scale Score
MCTA	multi-detector computed tomography angiography

NECT	non-enhanced computed tomography
OKM	O'Kelly Moratta Occlusion Classification
PED	the pipeline embolization device
PHASES	Population Hypertension Age Size Subarachnoid hemorrhage
RR	Raymond Roy occlusion classification
SAC	stent-assisted coiling
SAH	subarachnoid haemorrhage
SE	the Surpass Evolve
TOF	time-of-flight
Pcom	posterior Communicating Artery
UIATS	Unruptured Intracranial Aneurysms Treatment Score
WEB	the Woven EndoBridge
WEB-SL	the Woven EndoBridge single layer
WEB-SLS	the Woven EndoBridge single later sphere

# List of Original Publications

This dissertation is based on the following original publications, which are referred to in the text by their Roman numerals:

- I Alpay K, Nania A, Parkkola P, Downer J, Lindgren AE, Rautio R. The outcomes of recurrent wide-necked intracranial aneurysms treated with the Woven EndoBridge (WEB): A retrospective bicenter study. *Journal of Neuroradiology*, 2022;49(3): 298-304.
- II Rautio R, Alpay K, Sinisalo M, Numminen J. Treatment of intracranial aneurysms using the new Surpass Evolve flow diverter: Safety outcomes and six-month imaging follow-up. *Journal of Neuroradiology*, 2022;49(1):80-86.
- III Alpay K, Hinkka T, Lindgren AE et al. Finnish flow diverter study: 8 years of experience in the treatment of acutely ruptured intracranial aneurysms. *Journal of Neurointerventional Surgery*, 2022;14(7): 699-703.
- IV Alpay K, Lindgren A, Rautio R, Parkkola R. The Woven EndoBridge for intracranial aneurysms: Radiological outcomes and factors influencing occlusions at 6 and 24 months. Full title of the publication. *Neuroradiology Journal*, published online ahead of print, 2022 Aug 26.

The original publications have been reproduced with the permission of the copyright holders.

# 1 Introduction

The incidence of intracranial aneurysms (IAs) in a population without comorbidities is 3% (M Vlak et al., 2011). Most IAs are incidentally diagnosed and never ruptures (Thompson et al., 2015). Factors associated with an increased risk of aneurysm rupture include Black and Hispanic ethnicity, hypertension, current smoking, alcohol abuse, use of sympathomimetic drugs, and an aneurysm larger than 7 mm (Lall et al., 2009; Vlak et al., 2012). The prevalence of IAs increases with age, with peak incidence age being 50–60 years. Furthermore, aneurysmal subarachnoid haemorrhage (aSAH) is 1.6-times more common in women; this preponderance begins after the fifth decade of life (N. K. de Rooij et al., 2007). Once an IA ruptures, blood leaks into the subarachnoid space causing subarachnoid haemorrhage, which accounts for 5–10% of strokes in the western world (Rincon et al., 2013). Aneurysmal subarachnoid haemorrhage is a significant cause of morbidity and mortality throughout the world, reaching the case mortality rate at one year as high as 50% (Korja et al., 2013). Although the incidence of aSAH varies widely among populations, likely due to genetic factors, comorbidities, and life habits (i.e., smoking), in a systematic review of population-based studies, the global incidence of aSAH ranges from 2 to 16 per 100,000 (Feigin et al., 2009). Notably, the incidence of aSAH in Finland during the last two decades has declined, while once it was the among the highest in the world—a decrease from 10 to 6 per 100,000 (Korja et al., 2016). The importance of aSAH to public health includes not only the burden of healthcare costs after aSAH but also survivors' significant loss of productive life (N. K. de Rooij et al., 2007). Nearly 25% of patients die before seeking care; for the remaining individuals, the leading cause of mortality and morbidity is rebleeding before the aneurysm is repaired (Korja et al., 2013, 2017). Thus, aneurysm repair in the setting of aSAH is crucial in preventing rebleeding.

Clinical experience and multi-center trials have proven that the treatment of ruptured IAs is safe and effective (Molyneux et al., 2009; Spetzler et al., 2020). The literature in the field generally recommends that ruptured IAs should be secured from re-rupture  $\leq 72$  hours (Connolly et al., 2012; Steiner et al., 2013). The treatment for unruptured IAs, however, is an area of uncertainty, as the evidence regarding the effectiveness of the routine treatment for unruptured IAs is lacking. Therefore,

several factors must be considered in selecting of the optimal management of an unruptured IA, including the size, location, and other morphological characteristics of the aneurysm; documented growth on serial imaging; the age of the patient; and a history of prior aSAH that may predispose a patient to a high risk of haemorrhage (Etminan et al., 2015; Greving et al., 2014). Treatment options include open surgical clipping or endovascular aneurysm obliteration; both treatments should be provided by specialized, experienced practitioners at high-volume centers (Boogaarts et al., 2014).

Aneurysm clipping was first performed by Dandy Walker in 1938; subsequently, Yasargil adapted microsurgical techniques to surgical aneurysm clipping (Davies & Lawton, 2014). Surgical clipping remains a reliable and efficient way to treat IAs. Three decades ago, Guglielmi introduced endovascular coiling (Guglielmi et al., 1991). Since then, upgraded versions of coils, stents, balloons, flow diverters, as well as many other new adjunctive intra- and extraluminal devices, have been developed for the treatment of IAs (Henkes & Weber, 2015).

With tremendous support from developments in innovative technologies, along with the evidence from large clinical trials, endovascular treatment has been the first choice for most IAs (Molyneux et al., 2015; Wiebers, 2003). In the context of intraluminal and intrasaccular flow dynamics, flow diverters and intrasaccular flow disturbers have developed. Thus, the effective treatment of more complex aneurysms that were once thought to be untreatable by conventional methods can now be treated by contemporary endovascular treatment.

## 2 Review of the Literature

### 2.1 Intracranial aneurysms

In a literal sense, an IA is the focal widening or dilatation of intracranial arteries. IAs are classified according to shape, such as saccular and fusiform, or pathogenesis, such as traumatic or infectious. Saccular aneurysms, which are the most common type, are berry-like lobular outpouchings of intracranial arteries and are most often located in bifurcations of the arteries in the circle of Willis (Clarke et al., 2005). In about 75% of affected patients, aneurysms are solitary lesions, whereas multiple lesions occur in about 25% of such patients (Rinne et al., 1994). Although there are some preclinical models and theories regarding how IAs develop, the development mechanism remains unclear. The majority of IAs causes no symptoms and are detected accidentally, more often owing to the high accessibility of head imaging. Aneurysms represent a significant health concern, predominantly because of significant morbidity and mortality associated with rupture and aSAH (Lawton & Vates, 2017).

#### 2.1.1 Epidemiology and risk factors

Researchers have reported the prevalence of IAs within varying ranges, as prevalence is affected by many factors, such as ethnicity, age, and sex. The prevalence of unruptured IAs in a population without comorbidities was estimated to be around 3%, and IAs are more prevalent in women than men (M Vlak et al., 2011). Although IAs are solitary lesions in most patients, 25% of patients have multiple IAs (Qureshi et al., 1998; Wiebers, 2003). IAs of anterior circulation are more common than those of posterior circulation (M Vlak et al., 2011; Wiebers, 2003).

IAs are not congenital disorders but develop over the life course; they are extremely rare in people under 20 years of age (Etminan et al., 2014). Furthermore, the formation of IAs is incompletely understood. Nevertheless, many researchers have managed to show association between several factors such as hypertension, female sex, and cigarette smoking (Inagawa, 2010; Juvela et al., 2001). Cigarette smoking and hypertension are independent risk factors for IAs, with an odds ratio of



3.0 and 2.9, respectively; combined, they have an odds ratio of 8.3 (Vlak et al., 2013). IAs are more common in females than males, even after adjusting for age and risk factors (M Vlak et al., 2011). Furthermore, people with a first-degree relative diagnosed with an IA have an increased likelihood of IA (Brown et al., 2008; Ronkainen et al., 1997). The risk of a saccular IA is also higher in those with some connective tissue-related genetic disorders. Autosomal dominant polycystic kidney disease is the most common disease associated with saccular IAs, with a relative risk of 6.9 (95% confidence interval, 3.5–14). Overall, 5–40% of autosomal dominant polycystic kidney disease cases also involve IA, with 10–30% of affected patients developing multiple IAs (Hitchcock & Gibson, 2017).

## 2.1.2 Common intracranial aneurysms

### 2.1.2.1 Saccular intracranial aneurysms

Generally, the IA refers to saccular outpouchings in intracranial arteries, with saccular IAs accounting for 85% of IAs. These berry-like IAs are frequently located at the bifurcation of arteries in the circus of Willis (Clarke et al., 2005). Although saccular IAs were once thought to be congenital, subsequent studies showed that this assumption was incorrect (Etminan & Rinkel, 2016). The pathogenesis of IAs has been studied in animal models, as well as in human specimens. It is very likely that inflammation and hemodynamic stress play pivotal roles in the formation of saccular IAs (Frösen et al., 2012). The death of medial smooth muscle cells in intracranial arteries and collagen disruption cause mismatches against hemodynamic stress, which together with apoptosis and inflammation in the arterial wall plays a key role in disease progression. In addition to the histological findings, many imaging-based studies have utilized contrast enhancement in or around the IA wall, highlighting inflammation in the pathogenesis (Edjlali et al., 2018).

Saccular IAs are categorized according to maximal diameter of the dome and maximum width of the neck. According to maximal diameter, historically saccular aneurysms are classified as following: small (<10 mm), large ( $\geq$ 10 mm), and giant ( $\geq$ 25 mm) (Meyers et al., 2009). The larger a saccular IA is, the higher is the risk of rupture, in daily practice IAs < 5 mm are considered small due to low risk of rupture (UCAS Japan Investigators et al., 2012). A saccular IA is wide necked if the width of the neck is  $\geq$ 4 mm or dome to neck ratio < 2 (Debrun et al., 1998; Fernandez Zubillaga et al., 1994).

### 2.1.2.2 Fusiform intracranial aneurysms

The term fusiform reflects the shape of an IA and not its underlying pathology (Mizutani et al., 1999). The fusiform IA is the less common morphologic type. Typically, there is circumferential dilatation of a segment of an intracranial artery—most frequently in the arteries of the vertebrobasilar system (Krings et al., 2011). The incidence of vertebrobasilar fusiform aneurysms is around 0.7% (Serrone et al., 2014). The pathology in the vessel wall of a chronic fusiform aneurysm is comprised of a dilated lumen and thinned wall (Krings et al., 2011). The natural history of chronic fusiform aneurysms is not well known. Furthermore, symptomatic chronic fusiform aneurysms are associated with high mortality and morbidity (Serrone et al., 2014). The risk of aSAH correlates to the size of the chronic fusiform aneurysms (Serrone et al., 2014). The symptoms are due to mass effect, cranial nerve palsies and brain stem compression, or ischemic strokes due to partial thrombosis of the IA (Mangrum et al., 2005; Nakatomi et al., 2020).

Surgical treatment of fusiform aneurysms is not only technically difficult but also poses a challenge owing to the perforating branches arising from the aneurysm lumen (Nakatomi et al., 2020). The clinical management for chronic fusiform IAs includes imaging follow-up and symptomatic treatment, as well as surgical or endovascular treatment, which are associated with a high risk of morbidity and mortality (Lawton et al., 2016; Nakatomi et al., 2020).

### 2.1.2.3 Dissecting intracranial aneurysms

The initial dissection of an intracranial artery may form a non-saccular, fragile aneurysm bulging out of the artery wall. Unlike saccular IAs, dissecting aneurysms usually do not occur at sites of bifurcation (Krings et al., 2011). Due to dissection, blood accumulates between media and adventitia, and the consequent false lumen can result in the bulging of the adventitia (Hara & Yamamoto, 2000; Krings et al., 2011). As the risk of re-rupture is as high as 65%, a ruptured dissecting IA requires hyperacute treatment (Mizutani et al., 1999). Treatment strategies for dissecting IAs are both surgical and endovascular, including the sacrifice of the proximal parent vessel and the wrapping of the parent artery (Krings et al., 2011). In the acute setting, flow diverter treatment as a contemporary treatment is feasible when conventional methods are not applicable (Rabinov et al., 2003).

## 2.1.3 Uncommon intracranial aneurysms

### 2.1.3.1 Infective aneurysms

The term “mycotic aneurysm” was used historically, although the causative agents of mycotic aneurysms can be fungal as well as bacterial infections. Thus, the historical term refers to shape of the aneurysm, not to the causative agent (Bergqvist, 2008). The incidence of mycotic IAs is only 2–6% of all IAs (Ducruet et al., 2010). The most common infectious disease associated with mycotic aneurysms is infective endocarditis, compromising almost 65% of all mycotic aneurysms (Ducruet et al., 2010). Although bacterial, fungal, and viral infections can cause mycotic aneurysms, the majority of mycotic IAs are caused by *S. Aureus* and *Streptococcus* species. Mycotic IAs tend to site commonly distal branches of circles of Willis because of the main underlying pathology, distal embolism (Ducruet et al., 2010).

The pathophysiology of mycotic aneurysms depends on how the causative agent spreads into the intracranial arteries. A direct invasion from adjacent tissues (e.g., cavernous sinus) can cause mycotic aneurysms in the proximal part of the internal carotid artery (ICA), whereas hematogenous spread in distal branches of intracranial arteries (Krings et al., 2011). Once the microorganisms reach the cerebral artery wall, an inflammatory reaction begins, including loss of the internal elastic lamina, infiltration of polymorphonuclear cells into the media and adventitia, and proliferation of the intimal cells. The inflammatory reaction in the arterial wall may eventually lead to either arterial ectasia or arterial wall rupture, forming a pseudoaneurysm. Morphologically mycotic IAs are like fusiform IAs, however there are mycotic IAs with extremely small necks, resembling saccular IAs (Krings et al., 2011).

Owing to their pathophysiology, mycotic aneurysms are more fragile than saccular IAs. The size of a mycotic IA does not predict the rate of rupture; contrary to saccular IAs, smaller mycotic IAs entail a higher risk of rupture. The most common symptom of mycotic IAs is SAH (Ducruet et al., 2010). However, some incidental mycotic IAs can remain unruptured, through the medical management of underlying disease (e.g., infectious endocarditis), the size of IAs might remain unchanged, sometimes even regress during the treatment. Intervention depends on rupture status and can be both surgical and endovascular treatments (Ducruet et al., 2010). Unruptured mycotic IAs have a 30% mortality rate due to the high mortality of underlying infectious diseases, while the mortality rate increases up to 80% when mycotic IAs rupture (Ducruet et al., 2010). Intervention depends on rupture status and can be both surgical and endovascular treatments (Ducruet et al., 2010).

### 2.1.3.2 Traumatic intracranial aneurysms

Traumatic IAs comprise only 1% of all reported IAs. The etiology of traumatic IAs includes both blunt and penetrating cranial trauma. Furthermore, traumatic intracranial aneurysms can be iatrogenic—for example, after transsphenoidal surgery or sinus surgery (Krings et al., 2008). Different rates of traumatic IAs have been reported after low-velocity (e.g., stub wounds) and high-velocity injuries (e.g., missiles), ranging between 0.1% and 8%. In contrast to saccular IAs, traumatic IAs are false or pseudoaneurysms, according to histological structure; in traumatic IAs, all three arterial layers are disrupted (Krings et al., 2011). Traumatic IAs can be categorized into three types according to location, as follows: (1) skull base (petrous/cavernous/supraclinoid), (2) subcortical or peripheral, and (3) distal cortical (associated with skull fracture and subdural hematomas) (Krings et al., 2008). The traumatic aneurysm of the ICA within the cavernous segment is the type most often encountered (48%) and is typically associated with basal skull fractures. Anterior circulation is commonly affected, particularly branches of the anterior cerebral artery (ACA; its relationship with the falx) and the middle cerebral artery (MCA; its relationship with pterion) (Krings et al., 2008). Very little is known about the natural history of traumatic IAs. In a relatively up-to-date study by Bell and colleagues, the average size of ruptured traumatic IAs was larger than unruptured (8.2 mm vs. 3.1 mm) (Bell, Vo, et al., 2010). The size of traumatic IAs tends to be associated with rupture. Traumatic IAs, unlike saccular IAs, are prone to rupture quickly. In the same study, the average time from diagnosis to rupture was  $15 \pm 10.7$  days (range: 4–32 days) (Bell, Vo, et al., 2010).

Surgery has been the mainstay treatment for traumatic IAs, although endovascular treatments, particularly in skull base injuries, have continued to evolve. sacrificing the parent artery by surgery or endovascular embolization (balloon, glue, coil) to stop bleeding is usually adequate. As traumatic IAs have no true lumen, conventional endovascular treatments, such as coiling, should be avoided due to very high risk of bleeding. However, reconstructive methods such as flow diversion, or stenting can be used in selected cases (Bell, Ecker, et al., 2010; Bell, Vo, et al., 2010). The mortality and morbidity of traumatic IAs mainly depends on the primary insult after the initial injury (Bell, Vo, et al., 2010).

### 2.1.3.3 Blister-like intracranial aneurysms

Blister-like IAs are comparatively small,  $<3$  mm, and typically occur along the dorsal wall of the ICA (Ishikawa et al., 1997). Although the original description of blister-like IAs involved lesions of the dorsal ICA wall (91%), more recent case reports and small clinical series have described aneurysms with similar characteristics in atypical locations, such as MCA, ACA, and the basilar artery (Peschillo et al., 2016). This

type of IA lacks internal elastic lamina and media, making these lesions highly fragile, thus prone to rupture (Ishikawa et al., 1997). Blister-like IAs are difficult to treat with conventional endovascular methods (i.e., coiling) or surgical clipping, owing to their shallow and fragile structure (Peschillo et al., 2016). Many surgical techniques, such as bypass and wrapping or scarifying the parent artery, are associated with a high risk of complications, with perioperative morbidity and mortality at a rate of 20% and 10%, respectively (Peschillo et al., 2016). In addition to deconstructive methods, coiling and surgery, reconstructive endovascular methods, flow diversion and stent-assisted coiling (SAC), have emerged with lower complication rates and better clinical outcomes than surgery (Peschillo et al., 2016).

#### 2.1.3.4 Pediatric intracranial aneurysms

Pediatric IAs accounts for 1–5% of all IAs (Garg et al., 2014). Unlike IAs in adults, pediatric IAs tend to be non-saccular, most commonly fusiform, and large (>10 mm) (Gross et al., 2015; Koroknay-Pál et al., 2012). The risk factors for IA growth in the adult population have been extensively studied. However, the pathophysiology of pediatric IAs is not clearly understood, as children are not exposed to risk factors associated with aneurysm formation in adults, such as cigarette smoking and hypertension. One can assume that pediatric intracranial aneurysms are congenital, but the data from large autopsy series has not proven this theory (Lasjaunias et al., 2005). Nevertheless, some genetically inherited diseases like polycystic adult-type kidney and tuberos sclerosis have been reported as underlying diseases in children with IAs by some authors (Koroknay-Pál et al., 2012; Lasjaunias et al., 2005). Furthermore, infection and head trauma were pointed to be etiologic factor for pediatric IAs (Koroknay-Pál et al., 2012). Although the pathology and morphology of pediatric IAs appear to be different than their adult counterparts, the clinical presentation of pediatric and adult IAs are the same—aSAH, followed by seizures and the mass effects of IAs (Gross et al., 2015; Koroknay-Pál et al., 2012). Pediatric patients with aneurysms, much like their adult counterparts, can be managed and treated both surgically and endovascularly. Surgical options for pediatric IAs include direct clipping, wrapping, the scarification of a parent artery, and trapping (Koroknay-Pál et al., 2012). Furthermore, endovascular methods include direct coiling, as well as balloon, or coil occlusion of the parent artery (Koroknay-Pál et al., 2012; Lasjaunias et al., 2005). Although the ongoing growth of cerebral arteries in children is a potential pitfall, there have been some reports on the successful treatment of pediatric IAs via flow diverter (Barburoglu & Arat, 2017; Navarro et al., 2015). Follow-up regarding a detected or treated pediatric IA is challenging because of the high recurrence rate and de novo aneurysm formation. Hence, lifelong follow-up has been purposed by some authors (Koroknay-Pál et al., 2012).

## 2.2 Subarachnoid hemorrhage

Subarachnoid hemorrhage (SAH) is the pathologic condition that exists when blood enters the subarachnoid space. The most common spontaneous SAH is the aSAH, accounting for 85% of all spontaneous SAH (Connolly et al., 2012). SAH resulting from a ruptured IA accounts for 5% of all strokes and carries an exceptionally high disease-specific burden; half of patients with aSAH are younger than 55 years, one-third die within the initial days to weeks after the hemorrhage, and most survivors have long-term disability or cognitive impairment (Nieuwkamp et al., 2009)

### 2.2.1 Incidence of aneurysmal subarachnoid hemorrhage

The global incidence of aSAH is estimated to be 9 per 100,000 people; however, it varies considerably according to age, sex, and geographic region (N. K. de Rooij et al., 2007). In recent reports, the global incidence of aSAH has appeared to decline, and in a meta-analysis by Etminan, the global incidence of aSAH was estimated to be 6 per 100,000, declining by 1.7% per 100,000 each year between 1955 and 2010 (Etminan et al., 2019). The incidence of SAH in Finland was once among the highest (20%) in the world; however, a recent study has shown that the incidence of aSAH in Finland has decreased significantly, dropping to 6–10 per 100,000 person-years (N. K. de Rooij et al., 2007; Korja et al., 2016). As aneurysm formation occurs gradually and is rare before 20 years of age, the incidence of aSAH is higher in people between 50 and 60 years of age (Nieuwkamp et al., 2009). With no regard to regional differences around the world, aSAH incidence is higher in women (Etminan et al., 2019).

## 2.3 Factors involved in aneurysm rupture

Several studies have investigated factors associated with aneurysm rupture. Much of our understanding of rupture risks relies on the data from the International Study of Unruptured Intracranial Aneurysms (ISUIA). Exactly why an aneurysm ruptures is still being elucidated, but several patient-specific, aneurysm-specific, and other factors have been identified.

### 2.3.1 Patient related factors

Cigarette smoking is single-handedly the most important risk factor for aneurysm rupture. Studies by Finnish investigators concluded that current smokers are three times more likely to experience a rupture than non-smokers (Korja et al., 2014). Furthermore, the important role of current smoking as an independent risk factor was

further underlined in a pooled analysis of 26 prospective cohort studies on aSAH risk factors (Feigin et al., 2009).

A family history of aSAH is also considered a risk factor for rupture. A family history of aSAH in two or more first-degree relatives increases the risk of rupture as high as 17 times (Broderick et al., 2009). However, in the Nordic twin-cohort study by Korja et al, it is found that the familial aSAH can be likely due to environmental factors rather than genetic inheritance (Korja et al., 2010). In the ISUIA study, the rate of rupture was 10-times higher in patients with prior history of aSAH than patients without history of aSAH, regardless of the location of the aneurysm (Murayama et al., 2016).

Increasing age (>60 years) has been identified as a risk factor for rupture. However, in the literature, the data is controversial on the relationship between increasing age and rupture. In a meta-analysis of 75 population-based studies, Etminan et al. found that increasing age is associated with rupture regardless of geographical factors (Etminan et al., 2019). Interestingly, in the same study, increasing age was more distinctly correlated with rupture in women aged >55 years (Etminan et al., 2019). On the contrary, young age at the time of rupture has been found to be predominant in males (N. K. de Rooij et al., 2007).

Furthermore, the relationship between hypertension and rupture has been studied. Striking data from a large prospective study, the study from Norway, showed that the risk of rupture increases gradually along with high systolic and diastolic blood pressure (hazard ratio: 2.3) (Müller et al., 2019). A notable result from a recent study was that high body mass index is associated with poor neurological outcome after surgically treated good grade aSAH (Rautalin et al., 2022)

### 2.3.2 Aneurysm related factors

The size and location of an IA are strongly associated with rupture. In their historically important study, Wiebers and colleagues clearly demonstrated that IAs <10 mm are unlikely to rupture (Wiebers, 2003). Years after this study, the ISUIA study supported this finding showing that aneurysms >5 mm had a hazard ratio of 12.24 compared to 2- or 4-mm IAs (Murayama et al., 2016). The location of an IA was an independent factor for rupture, as IAs located at the basilar tip and the vertebrobasilar and posterior communicating arteries had higher risk of rupture than their counterparts located on the ophthalmic and cavernous segments of the ICA (Murayama et al., 2016). Subsequently, the morphology of an IA is associated with rupture. The presence of a daughter sac was identified as a significant and independent risk factor for aneurysm rupture in a large Japanese cohort study conducted in 2012. In this study, UIAs with a daughter sac had a 1.6-fold increased

risk of rupture compared to aneurysms that had no daughter sac, irrespective of aneurysm size or location (UCAS Japan Investigators et al., 2012). Similar results were reported by the investigators of the ISUA study. In the ISUIA study, IAs with a daughter sac had a hazard ratio of 11 for rupture (Murayama et al., 2016). Furthermore, in their population-based study, Lindgren found that all sizes of IAs with irregular morphology are prone to rupture regardless of location and patient-related factors (Lindgren et al., 2016). In their prospective cohort study, Juvela et al. showed that with a median follow-up of 14 years, IA growth increases the rupture rate (Juvela et al., 2001). Aneurysm- and patient-related factors related to rupture are summarized in Table 1.

**Table 1.** Factors Associated with Aneurysm Rupture.

<b>Aneurysm Related Factors</b>
Size (>7 mm)
Irregular shape
Posterior circulation
Symptomatic aneurysm
Previous aSAH from other another IA
<b>Patient Related Factors</b>
Smoking
Hypertension
Family history of aSAH
Female sex
Increased age
Alcohol consumption

aSAH, aneurysmal subarachnoid haemorrhage.

According to the results of large prospective studies, several scoring charts regarding the treatment indication of UIAs have been developed. For instance, the PHASES (population, hypertension, age, size of aneurysm, earlier aSAH from another aneurysm, site of aneurysm) score was derived from the meta-analysis of studies on the natural history of IAs to establish the risk of rupture (Greving et al., 2014) The ISUIA and Japanese studies included 74% of the patients with aSAH in the PHASES meta-analysis; however, the generalizability of PHASES is uncertain and limited. Recently, Juvela et al. proposed a simple scoring chart that relies on the results of the longest follow-up of the Finnish cohort (Juvela, 2019). In this scoring, the size and location of the aneurysm as well as the patient’s current smoking status and age were considered.



## 2.4 Symptoms of aneurysmal subarachnoid hemorrhage

Clinical symptoms of aSAH can vary from mild headache to death before seeking care. The most classic symptom of aSAH is headache, which is often described as the “worst headache of my life” by patients. The onset of headache and how it peaks are more important than headache severity (Macdonald, 2014). Associated symptoms or signs include nausea, vomiting, or both; photophobia; neck stiffness; focal neurologic deficits; seizure; and brief loss of consciousness (Meurer et al., 2016).

IAs and aSAH can manifest along with many other symptoms depending on the location of the IAs. Especially before a rupture, the cranial nerve palsies of CN3, CN4, and CN6, as well as hemiparesis and aphasia, from a giant MCA-aneurysm (Meurer et al., 2016). In a study by Koskela, different ophthalmic palsies were seen in 9% of 121 consequent SAH patients (Koskela et al., 2015).

Several clinical grading systems have been introduced to predict outcomes at admission, including the World Federation of Neurosurgical Societies (WFNS) and Hunt and Hess (H&H) grading. The level of consciousness at admission, as measured by the Glasgow Coma Scale, is the most useful outcome predictor.

## 2.5 Diagnosis of subarachnoid hemorrhage and intracranial aneurysms

The first-line diagnostic imaging method for SAH is non-enhanced head computed tomography (NECT). In a multicenter prospective study investigating NECT in patients with headache typical of SAH, the sensitivity of NECT was found to be 100% if the imaging was done within 6 hours of symptom onset (Perry et al., 2011). Furthermore, in a systematic review by Edlow, the sensitivity of NECT was found to be 93% (CI 95%, 66–98%) (Edlow & Wyer, 2000). As with the progression of time, the sensitivity of NECT in the diagnosis of SAH decreases to 50% if NECT is done after 5 days of symptom onset.

Patients with aSAH in whom the diagnosis was initially missed had an unadjusted odds ratio of 3.4 of death at 3 months and of 4.7 at 12 months compared to those with similar clinical illness who were correctly diagnosed (Kowalski et al., 2004). Thus, if the probability of SAH is high in a NECT-negative patient, the next diagnostic method is the lumbar puncture (LP), which is 100% sensitive in the diagnosis of SAH. Several parameters can be evaluated regarding cerebrospinal fluid (CSF), such as visual investigation, red blood cell count, and spectrometry. In patients with sudden headache with a negative NECT but a positive LP, almost half had ruptured IAs (Horstman et al., 2012). However, LP also comes with risks, such as post-puncture headache and persistent CSF leak (Duits et al., 2016).

Once an SAH is detected by NECT, assuming that blood is typically spread in the subarachnoid space and basal cisterns, the next step is detecting the cause of the SAH. Multi-detector computed tomography angiography (MCTA) is a rapid, non-invasive, and cost-effective method to detect IAs. The reported sensitivity and specificity are around 98% and 100%, respectively, in revealing IAs (Agid et al., 2006). Apart from great accessibility, other advantages of MCTA are lower radiation exposure and lower costs compared to digital subtraction angiography (DSA) (Westerlaan et al., 2011). Several factors affecting sensitivity of MCTA for detecting IAs. For instance, aneurysm size and location are well-known factors affecting the diagnostic sensitivity of MCTA. In a meta-analysis by White, MCTA was shown to be more sensitive in detecting aneurysms larger than 3 mm (White et al., 2000). Another pitfall of MCTA in detecting IAs is the location of aneurysms. Regardless of any technological improvement to MCTA, detecting IAs close to the central skull base remains problematic due to the bony structures and complex vascular anatomy. In a meta-analysis of MCTA in the diagnosis of IAs, a double-reading is recommended for each negative MCTA; thus, the false negative rate can be reduced as low as 1% (Westerlaan et al., 2011).

The role of magnetic resonance imaging (MRI) is well established in many clinics as a follow-up method. However, in an acute aSAH setting, MRI is not a preferred imaging method in the diagnosis of ruptured intracranial aneurysms. This is mostly due to availability and patient-related factors such as altered mental status. In a study by Pierot et al., only half of the patients were eligible for MRI because of clinical status at admission (Pierot et al., 2013). In clinically eligible cases, three-dimensional time-of-flight magnetic resonance angiography (TOF-MRA) has high diagnostic value (>95% sensitivity, >95 specificity) (Chen et al., 2012). However, the size of the aneurysm and interobserver agreement were reported to be factors affecting the accuracy of TOF-MRA (Jäger et al., 2000).

Digital subtraction angiography (DSA) with three-dimensional rotation angiography is the gold standard in the detection of IAs. Because it is an invasive procedure, DSA comes with certain risks, such as neurologic deficits and groin and intraabdominal hemorrhage. The overall complication rate reported in large series is approximately 1.5%, and the rate of permanent neurologic deficit is 0.5% (Willinsky et al., 2003)(Dawkins et al., 2007). Certain procedure-related factors—e.g., duration of fluoroscopy and experience of the operator—are associated with complications. Dion et al. reported a significant increase in complication rates of DSA with fluoroscopy time >60 minutes (Dion et al., 1987). Patients older than 55 years and with vascular diseases are at risk of complications in DSA procedures (Willinsky et al., 2003). An estimated 15% of aSAH includes a negative initial DSA. Most DSA-negative spontaneous SAHs have a perimesencephalic pattern with no vascular

malformation. However, a causative IA has been found in 5% of patients with a repeat DSA on the seventh day after SAH (Delgado Almandoz et al., 2012).

## 2.6 Complications of aneurysmal subarachnoid hemorrhage

Rebleeding is the major cause of disability and mortality after aSAH (Juvela, 1989; Stienen et al., 2018). The incidence of rebleeding is high within the first 2 hours after aSAH (Ohkuma et al., 2001). Furthermore, over one-third of rebleeds occur within the first 3 hours, and almost half occur within 6 hours after aSAH (Tanno et al., 2007). Factors associated with early rebleeding <6 hours are high H&H grade (4–5), aneurysm size >10 mm, the presence of posterior circulation aneurysms, the presence of intracerebral or intraventricular hematoma, and high systolic blood pressure (Solanki et al., 2016; Tang et al., 2014). European and North American guidelines on the management of aneurysmal subarachnoid hemorrhage recommend tranexamic acid and blood pressure control (systolic blood pressure <160 mmHg) as a medical management and early intervention <72 hours to prevent rebleeding (Connolly et al., 2012; Steiner et al., 2013).

After the treatment of a ruptured IA, the most important cause of neurologic morbidity is delayed cerebral ischemia (DCI) due to cerebral vasospasm (Jabbarli et al., 2015). The angiographic incidence of vasospasm in patients with aSAH is as high as 70%, however DCI is seen approximately 30% of patients between 4<sup>th</sup> and 14<sup>th</sup> post-ictal days (Vergouwen et al., 2010). DCI and cerebral vasospasm are preventable causes of neurologic disability after aSAH; therefore, the diagnosis and management of these entities are crucial (Sadan et al., 2021). The underlying pathophysiology of DCI and angiographic vasospasm is complex and isn't completely understood. A cascade of reactions initiated by ictus includes vasospasm of large vessels, microthrombus formation in pial vessels and inflammatory reactions probably leads to perfusion mismatch and at the end ischemia (Foreman, 2016). The diagnosis of DCI relies on both clinical examination and imaging studies. The gold standard for detecting vasospasm is DSA, however it does not provide information on perfusion. CTA, CT-perfusion, and MRI are useful to identify potential ischemic areas of brain (Connolly et al., 2012; K. Li et al., 2019). Nimodipine, an oral Ca-channel blocker, is shown to improve neurological outcomes, not vasospasm, and is recommended to all patients with aSAH as prophylactic treatment (Connolly et al., 2012; Pickard et al., 1989). For last decades the Triple-H therapy (hypertension, hypervolemia, and hemodilution) has been the mainstay in the management of DCI (Sen et al., 2003), even though no randomized trials proved the benefit of triple-H therapy. Controversially, Gathier et al. recently showed that triple-H therapy can even lead to unfavorable neurological outcomes (Gathier et al., 2018). Developing

technology in neurointerventional radiology has given rise to treat cerebral vasospasm refractory to medical treatment. Intra-arterial balloon angioplasty, angioplasty with self-retrievable stents and intra-arterial infusion of vasodilators alone and combined to IA vasodilators for refractory vasospasm have been studied and found to be equal to medical treatment in terms of safety and neurological outcomes (Bhogal et al., 2017; Jestaedt et al., 2008; K. Li et al., 2019; Venkatraman et al., 2018).

The incidence of acute hydrocephalus after aSAH depends on whether the patient has symptomatic or radiological hydrocephalus. Thus, the reported incidence of hydrocephalus ranges between 9% and 67% (Black, 1986). The external ventricular drain (EVD) is the most common treatment of acute hydrocephalus, though in selected cases, a lumbar drain can be used (Connolly et al., 2012). Almost 20% of patients have shunt-dependent hydrocephalus after aSAH (Adams et al., 2016). Several factors have been found to be associated with shunt dependency, such as increased age, high Fisher grade, poor H&H grade, posterior circulation IAs, hydrocephalus at admission, and nosocomial meningitis (Rincon et al., 2010; Zaidi et al., 2015). Neither open surgical nor endovascular treatment is associated with chronic hydrocephalus (Zaidi et al., 2015).

Seizures or seizure-like episodes after aSAH are relatively common. The incidence is estimated to be almost one-third of patients with aSAH (Connolly et al., 2012); however, the incidence of in-hospital seizures is significantly lower, between 2% and 8% (Butzkueven et al., 2000) (Raper et al., 2013). Thus, most cases likely include seizure or seizure-like symptoms before the patient reaches a hospital. On the other hand, 20% of patients with high-grade aSAH (H&H grade 4–5) experience seizures (Claassen et al., 2004). Diagnosis is difficult, because whether the continuous EEG monitoring should be ordered for all patients or a subset of patients is unclear (Steiner et al., 2013). In retrospective analyses, factors predicting early seizures have been identified. The location of the aneurysm (middle cerebral artery), presence of intracerebral hemorrhage, rebleeding, and high H&H grade (IV–V) are linked to early seizures (Connolly et al., 2012; Raper et al., 2013). In the treatment of acutely ruptured intracranial aneurysms, patients who have undergone endovascular coiling have lower risk of seizure than patients who have undergone clipping (Hart et al., 2011); however, the risk seems to be equal in the treatment of unruptured IAs (Hoh et al., 2011). There is controversy and a lack of evidence in terms of the use of prophylactic antiepileptic drugs (Connolly et al., 2012; Steiner et al., 2013). Furthermore, the prophylactic use of antiepileptic drugs has also been related to unfavorable outcomes (Smith et al., 2021).

Raised intracranial pressure is associated with patients with poor-grade (H&H grade 4-5) aSAH. The management of raised intracranial pressure is tier based, and there is no consensus on guidelines. Most neurosurgical centers adapt a protocol

from traumatic brain injury guidelines for the management of raised intracranial pressure. The management of raised intracranial pressure includes placing an EVD, removing sizeable cranial clots (i.e., subdural hematoma, intracerebral hemorrhage), sufficient sedation, maintenance of normal body temperature, assisted ventilation, and hypertonic saline or mannitol boluses. The role of decompressive hemicraniectomy for raised refractory intracranial pressure is controversial, and there is a lack of evidence of its benefits. In a meta-analysis, the rate of poor patient outcomes in those who had undergone decompressive hemicraniectomy after aSAH was 62%, and the death rate was 28% (Alotaibi et al., 2017). The effect of decompressive hemicraniectomy on functional outcomes after aSAH remains unknown. Further randomized control trials are needed to clarify the true effect of decompressive hemicraniectomy for patients with aSAH.

Apart from neurologic complications of aSAH, there are several non-neurological complications affecting outcomes. Common cardiologic complications of aSAH include cardiac troponin abnormalities, arrhythmias, and cardiac dysfunction (Lee et al., 2006; van der Bilt et al., 2009). Although theories regarding the neurogenic stress cardiomyopathy and cardiogenic complications of aSAH have not been proven, it is thought that sympathetic stimulation induces catecholamine release in the myocardium, which could lead to several cascades and result in myocardial dysfunction (Lee et al., 2006). Several studies have been done on cardiologic complications after aSAH. In a meta-analysis by Van der Bilt, the cardiac complications of aSAH were found to be related to a high risk of delayed cerebral ischemia (DCI), poor outcomes, and death (van der Bilt et al., 2009). Venous thromboembolism, including deep vein thrombosis and pulmonary embolism, are common in critically ill patients. The incidence of venous thromboembolism in neurosurgical patients is between 0% and 30% (Raslan et al., 2010). The typical presentation of deep vein thromboembolism can be seen in only one-third of cases. In a study by Ray et al., patients with aSAH had daily follow-up with duplex doppler ultrasound for detecting venous thromboembolism, and the incidence of deep venous thromboembolism was 18% (Ray et al., 2009). Venous thromboembolism seems to peak within the first two weeks after aSAH (Liang et al., 2015). The current guidelines recommend prophylactic treatment, after securing ruptured IAs, for venous thromboembolism for patients with aSAH (Steiner et al., 2013). Patients who have had an aSAH are prone to several other medical complications. Of these, common medical complications associated with worse outcomes after aSAH are electrolyte disturbances including cerebral salt-wasting syndrome, central fever, and hyperglycemia (Frontera et al., 2006; Rahman & Friedman, 2009; Wartenberg et al., 2006). The medical management of patients with aSAH goes far beyond the surgical and endovascular treatment of IAs. It has been shown that better outcomes after

aSAH can be achieved with a dedicated neurocritical care unit (O. Samuels et al., 2011). Common complications of aSAH is summarized in table 2.

**Table 2.** Common Complications of Aneurysmal Subarachnoid Hemorrhage.

<b>Neurologic Complications</b>	<b>Medical Complications</b>
Rebleeding	Pneumonia
Delayed cerebral ischemia	Pulmonary embolism
Hydrocephalus	Adult type respiratory distress syndrome
Seizures	Cardiac arrhythmias
Intracerebral hemorrhage	Myocardial infarction
Direct effect of aSAH	Gastrointestinal bleeding
	Other infections (wound infections etc.)
	Hyperglycemia
	Hyponatremia
	Diabetes insipidus

aSAH, aneurysmal subarachnoid haemorrhage.

## 2.7 Neurological outcome after aneurysmal subarachnoid hemorrhage

Many survivors after aSAH are in their most productive years and have major responsibilities with respect to work and family. Multiple outcome scales have been developed to assess functional outcomes after various brain injuries, such as the Glasgow Outcome Score (GOS), modified Rankin Scale (mRS), Short Form 36, mini-mental state examination (MMSE), Montreal Cognitive Assessment, and Barthel Index. No scale has been developed specifically for aSAH. Several studies have aimed to facilitate decision-making for treating physicians; in these studies, factors predicting outcomes after aSAH were analysed. The most important factor determining outcomes after aSAH is the neurological condition at admission, which can be assessed using the WFNS grading scale (Jaja et al., 2013; Mocco et al., 2006; van Donkelaar et al., 2019). Furthermore, high age, severe clot burden of aSAH, and aneurysm size are predictive factors of clinical outcomes (van Donkelaar et al., 2019). In International Subarachnoid Hemorrhage Aneurysm Trial (ISAT) ISAT, the neurological outcomes of patients treated endovascularly were found to be better; however, in the Barrow Ruptured Aneurysm Trial (BRAT), after one year, there was no statistically significant difference found between microsurgical clipping and endovascular treatment (Molyneux et al., 2005; Spetzler et al., 2020).

Cognitive impairments are most frequent within the first three months after aSAH. However, studies have demonstrated that residual cognitive impairments can

persist as long as 75 months after aSAH, perhaps longer (Benke et al., 2005). Verbal, visual, short-term, and long-term memory have all been investigated after aSAH. Older age, fewer years of education, poorer neurological grade on admission, ruptured aneurysms in the anterior circulation, and thick subarachnoid blood in the anterior interhemispheric fissure and sylvian fissures have been shown to be associated with poorer performance on tests of verbal and visual memory (Kreiter et al., 2002). In addition to impairments in both visual and verbal memory, a range of 3–76% of patients suffer from impairments in executive function, encompassing higher-level cognitive abilities like planning, inhibition, problem-solving, attention, and decision-making. Language function involves both comprehension and expression both orally and literally. It is estimated that the prevalence of language impairments is seen in up to 70% of patients depending on patient- and aneurysm-related factors, such as age, education level, and aneurysms in anterior circulation. The good news is that language impairment starts to resolve 3 months after aSAH and continues to improve until 18 months (Al-Khindi et al., 2010). The components of functional outcomes for which the assessment tools have been developed include activities of daily living, instrumental activities, and the ability to return to one's previous occupation. One of the most important components of real-world functioning is the ability to return to one's previous occupation. Most studies estimate that among patients who were employed before aSAH, up to 40% are unable to return to their previous occupation (Vilkki et al., 2004). Activities of daily living (ADLs) are those one performs for self-care. Examples of ADLs include feeding, grooming, dressing, bathing, and toileting. ADL impairments are not as prevalent in comparison to some cognitive impairments; studies indicate that deficits in ADLs are present in 4% to 12% of patients who have experienced aSAH (Noble et al., 2008). Instrumental activities of daily living (IADLs), which include managing financing and shopping, are more complex than ADLs and are more frequently impaired with an estimated prevalence of 44–93% (Al-Khindi et al., 2010). Cognitive and functional outcomes are also influenced and complicated by mood, anxiety, sleep, fatigue, and method of neurosurgical treatment (e.g., clipping or coiling) (Hadjivassiliou et al., 2001).

Over the last 20 years, clinical outcomes have improved, along with decreasing mortality after aSAH, due to better diagnostic tools and neurointensive care utilization (Dhandapani et al., 2018; Lovelock et al., 2010; O. B. Samuels et al., 2021). However, aSAH remain challenging due to controversial results from studies the management and decision-making for poor-grade (H&H 4–5) (Inamasu et al., 2016; Ojha et al., 2020).

**Table 3.** Modified Rankin Scale Score.

0	No symptoms
1	No significant disability despite symptoms; able to carry out all usual duties and activities
2	Slight disability; unable to carry out all previous activities, but able to look after own affairs without assistance
3	Moderate disability; requiring some help, but able to walk without assistance
4	Moderately severe disability; unable to walk without assistance and unable to attend to own bodily needs without assistance
5	Severe disability; bedridden, incontinent and requiring constant nursing care and attention
6	Dead

## 2.8 Treatment of intracranial aneurysms

The main goals of both endovascular and surgical treatment for any given IA are reducing the risk of IA rupture or rebleeding and maintaining patients' neurologic condition. The decision to treat an unruptured IA is more complicated than that to treat a ruptured IA because of controversial data and lack of evidence. The benefits of treating an unruptured IA should be weighted carefully by an experienced neurovascular team, keeping in mind that most IAs never rupture. Many other variables related to patients and aneurysms have profound effects on the decision.

A ruptured intracranial aneurysm should be treated within 72 hours after the diagnosis of SAH because the mortality of rebleeding is as high as 90% (Connolly et al., 2012; Korja et al., 2017; Steiner et al., 2013) the surgical or endovascular treatment of ruptured IAs is well established. Understandings the natural history of unruptured IAs come from large clinical trials, including the ISUIA. According to results of the ISUIA, regardless of criticism by experts, most unruptured intracranial aneurysms occurring in patients with no previous history of aSAH can be managed conservatively (“Unruptured Intracranial Aneurysms — Risk of Rupture and Risks of Surgical Intervention,” 1998). The cumulative risk of rupture for aneurysms <10 mm for patients with no history of aSAH was 0.05% per year (“Unruptured Intracranial Aneurysms — Risk of Rupture and Risks of Surgical Intervention,” 1998). However, in prospective studies done in Finnish and Japanese populations, the risk of rupture for aneurysms <7 mm should not be ignored (Korja et al., 2014; “The Natural Course of Unruptured Cerebral Aneurysms in a Japanese Cohort,” 2012). In the second part of the ISUIA study, the annual rupture rate of aneurysms <7 mm was 0% for anterior circulation and 2.5% for posterior circulation aneurysms. Apart from the size of an unruptured IA, certain factors were found to be associated with rupture, such as posterior circulation location, female sex, smoking history, and multiple IAs (Korja et al., 2014; “The Natural Course of Unruptured Cerebral Aneurysms in a Japanese Cohort,” 2012; Wiebers, 2003). Some scoring systems—



i.e., PHASES and UIATS—based on patient- and aneurysm-related factors anticipating rupture were introduced to help clinicians in their decision-making (Etminan et al., 2015; Greving et al., 2014).

### 2.8.1 The microsurgical clipping

The first clipping of an IA was reported by Walter Dandy in 1938 (Dandy, EW. Intracranial Aneurysm of the Internal Carotid Artery Cured by Operation. *Ann Surg* 1938; 107: 654–659, n.d.), and clipping remains the gold standard after developments in microsurgery and operating microscopes. In the modern era, the neurovascular surgeon opens the skull (craniotomy) and dissects the arachnoid under an operating microscope to expose an IA. Once the IA is exposed, a titanium clip is placed across the neck of the IA while preserving the parent artery (Lawton & Vates, 2017). Immediate radiological outcomes after microsurgical clipping can be assessed via indocyanine green video angiography during operation (ICG-VA) (Riva et al., 2018). The following approaches to intracranial aneurysms are common: pterional craniotomy, orbitozygomatic craniotomy, and far-lateral craniotomy (Davies & Lawton, 2014).

During the last two decades, the microsurgical clipping of unruptured intracranial aneurysms has declined due to the results of large multicenter trials, along with huge technologic developments in endovascular treatment. The surgical treatment of unruptured intracranial aneurysms provides high survival rates (Britz et al., 2004). The mortality and morbidity attributed to surgery for unruptured IAs in a meta-analysis including studies between 1966 and 1996 were found to be 2.6% and 10.9%, respectively, whereas in a meta-analysis including studies between 1990 and 2011, mortality and morbidity were found to be 1.7% and 6.7%, respectively. In contrast to these meta-analyses, surprisingly high—almost 15% at 1 year—morbidity and mortality rates attributed to surgery were reported in the ISUIA 1 study (“Unruptured Intracranial Aneurysms — Risk of Rupture and Risks of Surgical Intervention,” 1998). In the subsequent study, ISUIA 2, by the same investigators, the in-hospital mortality rate was 1.8%, and adverse outcomes were seen in 8.9% of patients (Wiebers, 2003). When looking deeper into the results of large meta-analyses, ISUIA 1 and ISUIA 2, several patient- and aneurysm related factors were associated with morbidity and mortality attributed to surgery for unruptured IAs. The risk significantly increased in patients >50 years, increasing substantially over 60 years of age (Wiebers, 2003). Other factors predicting morbidity and mortality include IA size, location in posterior circulation, and the presence of symptomatic IAs (Raaymakers et al., 1998; Wiebers, 2003).

Our understanding of outcomes after this microsurgery comes from the BRAT and ISAT studies. Microsurgery was the only treatment for ruptured IAs before the

introduction of coiling in 1991. The only existing large multicenter randomized trial on the treatment of ruptured IAs is the ISAT. Although, the BRAT was a single-center study, BRAT and ISAT provide data for decision-making on the current treatment of ruptured IAs. In these two randomized trials assessing the safety and effectivity of coiling and clipping, microsurgical clipping results much lower re-treatment rate; 3.9% and 4.5% in the ISAT and BRAT, respectively (Campi et al., 2007; Spetzler et al., 2020). In addition to low re-treatment rates, in the BRAT trial, the complete obliteration rate in the aneurysms treated with clipping was 93% at 10 years (Spetzler et al., 2020). The risk of rebleeding from the target aneurysm after microsurgical clipping was studied in both trials, and in the BRAT, there was no rebleeding (0/175) at 10 years; in the ISAT, rebleeding occurred in 13 cases (Molyneux et al., 2009; Spetzler et al., 2020).

In conclusion, microsurgery provides significantly low rebleeding rates, along with a high occlusion rate. The pure morbidity and mortality attributed to the microsurgery for ruptured IAs is a difficult aspect to investigate because of the high mortality and morbidity rates in aSAH. The results of the 10-year follow-up in the ISAT showed that dependency and death were found to be associated with the microsurgery (Molyneux et al., 2015). In contrast, the microsurgery wasn't found to be associated with neurological dependency or death at 10-year follow-up in BRAT (Spetzler et al., 2020). The experience of a neurovascular surgeon and the volume load of the tertiary center are associated with a low rate of surgical complications (Lawton & Vates, 2017; Steiner et al., 2013). Furthermore, certain factors were found to be associated with functional independence after microsurgery for ruptured IAs. Particularly, large (>10 mm) and giant aneurysms (>25 mm), aneurysms with an atherosclerotic neck, and aneurysms at the anterior communicating artery or basilar bifurcation are more frequently associated with surgical complications.

A subtype of aSAH for which surgery can be considered as a sole option is aSAH with intracerebral hematoma (ICH). ICH due to the rupture of IAs occurs in 10–38% of cases with aSAH (Darkwah Oppong et al., 2018). There is data in favor of the surgical evacuation of ICH and aneurysm clipping from a randomized trial (Heiskanen et al., 1988); however, the evidence is still weak. Furthermore, the overall mortality of patients with ICH from a ruptured IA, regardless of ICH evacuation, has been reported at 39–42% (Bohnstedt et al., 2013; Talamonti et al., 2016). Considering the median mortality rate of SAH, between 40% and 44%, the benefit of clot evacuation and clipping in the same session may be doubtful. Outcome-predicting factors, such as a high grade of SAH at admission, a large volume of ICH, and high age, were found (Darkwah Oppong et al., 2018; Güresir et al., 2008) However, the subtype of patients who can benefit from ICH evacuation and clipping in the same session is unclear, and controlled trials are needed.

Microsurgical clipping is mainly suitable for saccular intracranial aneurysms (Lawton & Vates, 2017). The surgical treatment options for giant and fusiform IAs are bypass and Hunterian ligation (Nakatomi et al., 2020; Sughrue et al., 2011). A detailed discussion of these surgical approaches is beyond the scope of this thesis. Although surgical therapy has developed significantly along with better peri- and post-operative care, these surgical treatments still carry a high risk of morbidity and mortality. In a nationwide analysis of bypass surgery for IAs, the overall morbidity and mortality were found to be 56.3% and 7.3%, respectively (Winkler et al., 2019). The high risk of bypass, apart from the inherent risks of aneurysm surgery, is due to several other factors related to fusiform and giant aneurysms, such as merciless anatomy, wide necks, atherosclerotic degeneration, and perforators (Sughrue et al., 2011).

## 2.8.2 The conventional endovascular treatment

### 2.8.2.1 The simple coiling

It has been 30 years since Guglielmi introduced detachable coils as an alternative treatment option for IAs. In this treatment, a microcatheter is advanced into the aneurysm, and the aneurysm is occluded with soft titanium detachable coils (Guglielmi et al., 1991). In his paper, in which he also reported the method, 15 patients successfully were treated for IAs; eight of these aneurysms were ruptured, with no treatment-related mortality and no permanent neurological deficits (Guglielmi et al., 1991). Since then, the coil embolization of IAs has been in continuous evaluation and development, providing the potential to treat IAs that were once thought be untreatable. After endovascular treatment was proven to be safe and efficient in international multicenter trials, coil embolization has surpassed microsurgery in the western world (Lin et al., 2018). IAs with narrow necks in any given location could be suitable for coil embolization.

Several papers, including meta-analyses and multicenter randomized clinical trials, have reported on the safety and efficacy of coil embolization over the last two decades. Coil embolization for unruptured IAs has proven to be safe with low mortality and morbidity related to the treatment. In a nation-wide study in United States study, Brinjiki et al. showed a mortality rate of 0.9% and morbidity rate of 4.9%; furthermore, coiled patients had an in-hospital mortality rate of 0.6% (Brinjikji et al., 2011). Two recent meta-analyses regarding the safety of simple coiling have reported similar risk of mortality—0.2–0.8% (Krag et al., 2021; O'Neill et al., 2017). The most common complication of coil embolization is thromboembolism. The reported rate of incidence was between 3% and 10%; the rate of incidence for permanent neurological deficits was 1.7–5% (Park et al., 2008). Other complications

of coil embolization are cerebral vasospasm, iatrogenic SAH, and groin hemorrhage (Eskridge et al., 1998). A significant debate between neurovascular surgeons and neurointerventionists is regarding aneurysm recurrence after coil embolization and the risk of aneurysm rupture. It is estimated that almost 20% of aneurysms treated with coiling involve recurrence (Ferns et al., 2009). Unruptured aneurysms treated with simple coiling seem to rupture extremely seldomly. Pierot et al. showed a rupture rate of 0% for unruptured IAs after coil embolization in their study (Pierot, Barbe, et al., 2020). Additionally, a nation-wide study in South Korea by Kim et al., which included 14,634 unruptured IAs treated with coiling in South Korea, found a cumulative rupture rate of 0.9% at 7 years after treatment (Y. D. Kim et al., 2018). Regarding neurological outcomes after coil embolization, in a recent meta-analysis, the outcomes of patients having undergone coiling were found to be better than those for microsurgical clipping in all follow-up periods and all randomized and non-randomized studies (Falk Delgado et al., 2017). The size of the neck was found to correlate with angiographic outcomes after simple coiling, and IAs with narrow neck (<4 mm or dome-to-neck ratio >2) were most suitable for simple coiling in terms of adequate radiological outcomes (Debrun et al., 1998; Fernandez Zubillaga et al., 1994). Apart from the size of the neck and the packing density at the initial treatment, aneurysms >10 mm and partial thrombosis of aneurysm have been found to correlate with inadequate radiological outcomes (Ferns et al., 2009; Sluzewski et al., 2004; Vallee et al., 2003). Platinum coils have gone through technological development since 1991. Although though Ferns et al. did not report differences between types of coils used in embolization in terms of radiological outcome (Ferns et al., 2009), a recent study on hydrocoils, Heat Trial, reported that the adequate occlusion was better with hydrocoils than bare platinum coils in coil embolization for small- and medium-sized aneurysms (Bendok et al., 2020).

In the BRAT and ISAT, coil embolization of ruptured IAs were studied in details (Molyneux et al., 2009; Spetzler et al., 2020). Coil embolization for ruptured IAs provides good neurological outcomes and low mortality after aSAH according to the results of the ISAT (Molyneux et al., 2009). The proportion of retreated IAs after coil embolization at one year was 17.4% (191/1096) in ISAT and 20% (23/115) in the BRAT, as noted by the authors (Campi et al., 2007; Spetzler et al., 2020). The median duration from the initial treatment to retreatment in the ISAT was 13.7 months; on the other hand, in the BRAT, most of the retreatments were done within the first year after the initial coil embolization (Campi et al., 2007; Spetzler et al., 2020). Factors associated with retreatment after initial coil embolization were found to be younger age, large lumen, and low packing density at initial coiling in the ISAT (Campi et al., 2007). Rebleeding after the coil embolization for ruptured IAs is a major concern for treating physicians. The possible causes for rebleeding are coil packing and aneurysm growth. Rates of rebleeding were 3.0% during the first year,

and 0.3% between the second and sixth years; no rebleeding occurred after 6 years in the ISAT study (Molyneux et al., 2005, 2009).

### 2.8.2.2 The balloon- and stent-assisted coiling

Although most IAs are amenable for simple coiling without adjunctive techniques, coil embolization of certain aneurysms, particularly large and wide-necked, is not feasible. Moret et al. reported 56 cases treated with balloon-assisted coiling—or what they called the “remodeling technique” in 1997 (Moret et al., 1997). In balloon-assisted coiling, an inflatable and non-detachable balloon is placed across the aneurysm neck to optimize coil placement and provide dense packing (Moret et al., 1997). The advantage of balloon-assisted coiling over simple coiling is better initial and long-term radiological outcomes. In a meta-analysis, adequate occlusion was seen in 90% of IAs treated with balloon remodeling (Shapiro et al., 2008). High adequate occlusion rates, over 90%, were seen in the prospective multicenter ATENA and CLARITY studies (Pierot et al., 2010, 2011). Of major concern regarding balloon remodeling are the complication rates of thromboembolic events along with intraoperative rupture (Pierot et al., 2012). Although IAs treated with balloon remodeling are anatomically challenging, the complication rates are like those of simple coiling. In the CLARITY and ATENA studies, balloon-assisted coiling was found to be as safe as simple coiling (Pierot et al., 2009, 2011)

Intracranial self-extendable stents were invented at the beginning of the 2000s have become popular given that stent-assisted coil embolization is a feasible treatment for unruptured IAs with a wide-neck, and provide high adequate occlusion rates with an acceptable complication rate. The shortcoming of simple coiling—high recurrence rates—is not a common issue after SAC. The possible mechanisms behind low recurrence rates with SAC alteration in flow dynamics, increase packing attenuation, and favor thrombosis; these mechanisms may also provide scaffolding for endothelial growth (Peluso et al., 2008; Phatouros et al., 2000). The reports from several case series have shown a recurrence rate of 5–12% after SAC (Chalouhi et al., 2013; J. Kim et al., 2021; Shapiro et al., 2012). The reported rate of adequate occlusion after SAC for IAs is almost 90%, which can be as high as 80% after the simple coil embolization. IAs larger >10 mm are prone to recanalize after SAC (Chalouhi et al., 2013; Consoli et al., 2016). Complications related to SAC do not differ from simple coiling. However, a major concern with SAC is the necessity of dual-antiplatelet therapy, which can make patients prone to hemorrhagic complications, especially in the setting of aSAH. In a meta-analysis by Shapiro et al., the overall complication rate of SAC was found to be 19% (Chalouhi et al., 2013; Shapiro et al., 2012). However, in a recent meta-analysis, the overall complication rate was found to be 12%, which was significantly lower than the rate reported by

Shapiro et al (Phan et al., 2016). This difference in overall complication rates may be due to the development of stent technology and better understandings of management for dual-antiplatelet therapy. The study by Shapiro et al. included an analysis of studies published at the beginning of the SAC era. In later studies, thromboembolic and hemorrhagic complications occurred in 4.5% and 4% of patients, respectively (Feng et al., 2016; Phan et al., 2016). The mortality rate of SAC has been reported. In a meta-analysis by Feng et al., the mortality rate after SAC was 1.4% (n=31/2241) (Phan et al., 2016). Mortality related to SAC has been associated with the type of stent used; higher mortality rates were seen for balloon-expandable stents than for self-expandable stents (Piotin et al., 2010). Furthermore, patients with large aneurysms >10 mm have a higher risk of mortality in SAC (Phan et al., 2016).

SAC for acutely ruptured IAs is controversial due to higher overall, thromboembolic, and hemorrhagic intracranial complications compared to simple coiling. This is mainly due to the prothrombotic state of aSAH and dual-antiplatelet therapy (DAPT). The overall complication rate of SAC for acutely ruptured IAs has been reported as 21% (Bsat et al., 2020; Tähtinen et al., 2009). Intraprocedural rupture and acute re-rupture rates have been reported at 3.9% and 2.5%, respectively (Bsat et al., 2020). Some hemorrhagic complications of dual-antiplatelet treatment can be avoided. For instance, an external ventricular drain should be placed before SAC (Kung et al., 2011). Another widely used method to avoid complications associated with SAC is staged treatment, as follows: coil first to secure and, reduce the risk of re-rupture, and future stent it (Yang et al., 2015). The reported intraprocedural rupture and re-rupture rates in SAC were 3.9% and 2.5%, respectively (Bsat et al., 2020). Further analysis by Chalouhi et al. and Yang et al. have demonstrated that older age (>65 years), ruptured aneurysm, H&H grade IV–V, and female sex were independent risk factors for unfavorable clinical outcomes when treating wide-necked aneurysms with SAC (Chalouhi et al., 2013; Yang et al., 2015). Although the hemorrhagic and overall complication rates—8% and 12%, respectively—were higher for SAC for acutely ruptured IAs, the good clinical outcomes (mRS<2) of patients treated with SAC for acutely ruptured IAs were found to be between 51% and 71% (Bsat et al., 2020; Chalouhi et al., 2013; Tähtinen et al., 2009).

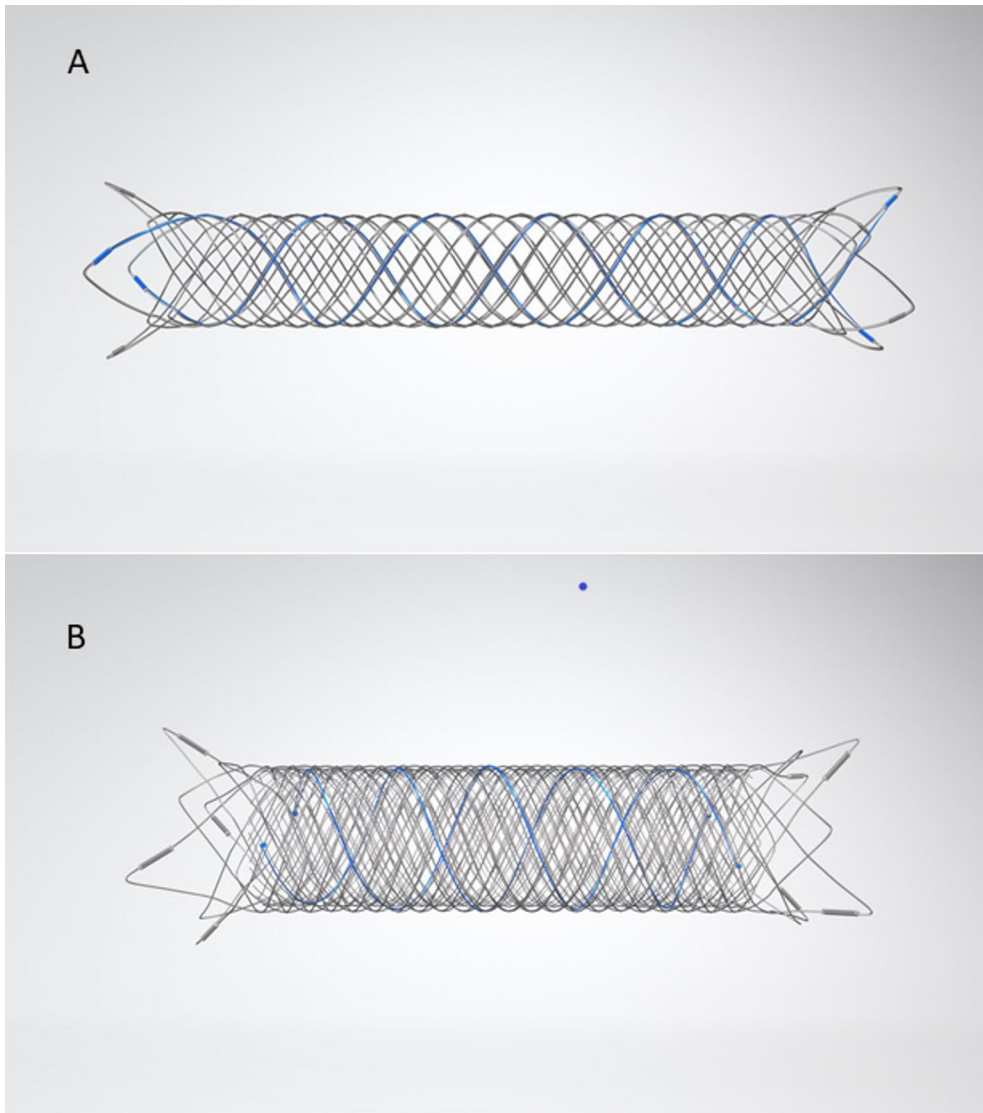
**Table 4.** Factors Associated with Inadequate Radiological Outcome After Coil Embolization.

Initial Coil Density <40%
Large Aneurysms >10 mm
Wide-Necked ≥4 mm
Aneurysm location

## 2.8.3 The contemporary endovascular treatment

### 2.8.3.1 Intraluminal flow diversion

Dissecting, blister-like, and fusiform aneurysms have challenging anatomy and pathology for conventional endovascular methods like simple coiling, SAC, or balloon-assisted coiling. Flow diverters (FDs) are mesh stents that are implanted into cerebral arteries at the site of aneurysms. The name “flow diverter” refers to the effect they cause in flow metrics, reducing the flow into and out of IAs. The ability of flow diverters to reduce flow lies behind its different structure than self-expanding closed-cell intracranial stents used in SAC. Furthermore, unlike conventional intracranial stents, flow-diverter stents are designed to have low radial opening force to facilitate navigability in torturous vessels. A braided metallic design makes possible greater metal coverage and decreased porosity for most FDs (Dmytriw et al., 2019). To understand how flow diverters function, there are a couple terms that must be understood—porosity and pore density. Porosity and pore density effect device permeability, and therefore the efficacy of device treatment. Porosity is the percentage ratio of metal-free surface to total surface area. Pore density is the number of pores per unit surface area. The pore structure of a flow diverter primarily effects flow alterations. The optimal porosity of 70% can be sufficient to treat IAs with FDs (Zhang et al., 2019). Even though the efficacy of an FD depends on the porosity, it is also understood that more refined conclusions should be provided with patient-specific geometries and a fully resolved FD model (Y. H. Kim et al., 2010). The pipeline embolization device (PED, Medtronic, Dublin, Ireland), commonly known as a pipeline or PED, was the first flow diverter approved by the European Medicines Agency (EMA) and Food Drug Administration (FDA) in 2008 and 2011, respectively (Maragkos et al., 2020). In 2018, the Surpass Streamline Flow Diverter (Stryker, Kalamazoo, Michigan) received FDA approval. In the European market, there are several more flow diverter devices commercially available, such as the flow-redirection endoluminal device (FRED; Microvention, Aliso Viejo, California), SILK (Balt Extrusion, Montmorency, France), Derivo (Acandis, Pforzheim, Germany), and p64 (Phenox, Bochum, Germany).



**Figure 1.** The structural difference between a self-expanding intracranial stent (A) and a flow diverter stent.

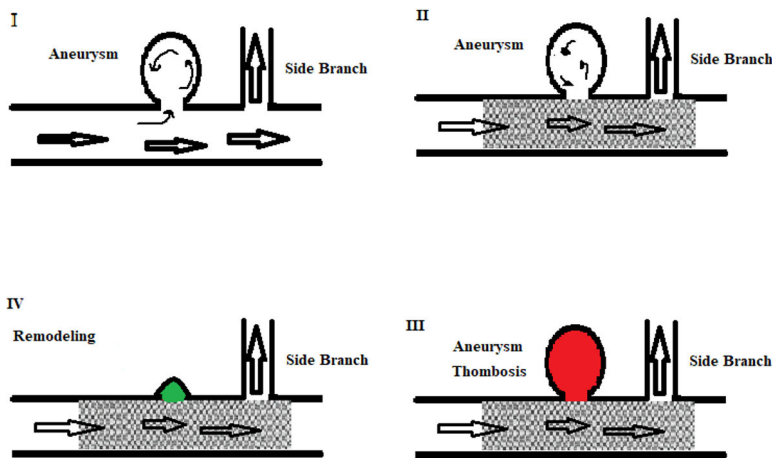
Although flow diverters have been on the market for slightly over a decade, their role in the treatment of unruptured IAs is well established. Starting with the treatment of para-clinoid aneurysms, a wide range of unruptured IAs, such as IAs located in the posterior and distal anterior, as well as bifurcations, are amenable for flow-diverter treatment. Several studies, retrospective as well as prospective observational, have been published on the safety and efficacy of flow diverters. Flow diverters provide a 90% rate of occlusion, with acceptable complication rates



(Brinjikji et al., 2013; Chancellor et al., 2020). Some studies have shown the occlusion of IAs after flow-diverter treatment to be gradual. In a multicenter prospective trial, large and giant aneurysms treated with a PED showed progressive occlusion, and the proportion of occluded IAs increased over time, from 86.8% at 12 months to 95.2% at 5 years (Beckske, Brinjikji, et al., 2017; Beckske, Potts, et al., 2017). Complications related to flow diverter treatment can be classified as thrombogenic, and hemorrhagic. In a recent meta-analysis including studies published up to 2016, the overall complication rate of flow-diverter treatment for unruptured IAs was found to be 14.6%. In these meta-analyses, the morbidity and mortality rates for unruptured IAs were not reported separately. On the other hand, in a previous meta-analysis, including studies published up to 2012, the morbidity and mortality related to flow-diverter treatment for unruptured IAs were 5% and 4%, respectively (Brinjikji et al., 2013). Furthermore, in a recent paper investigating the safety of the new generation Pipeline Flex-Shield, the overall and major complications—symptomatic ischemic and hemorrhagic stroke—were reported at 10.1% and 1.8%, respectively, along with an 0.8% mortality rate within 30 days. (Bhatia et al., 2019). When we look at the results of the studies conducted earlier, the difference in rates of complications attributed to flow-diverter treatment could be explained by the learning curve of treating physicians, as well as the development of technology. The presence of aSAH after flow-diverter treatment is of major concern to treating physicians. The rate of aSAH after flow-diverter treatment for unruptured IAs was found to be 4% including early (<30 days) and late (>30 days) (Brinjikji et al., 2013). In a prospective multicenter study investigating a new-generation flow diverter, no aSAH bleeding occurred after the treatment (Martínez-Galdámez et al., 2017). The occlusion of a jailed perforate artery is a specific complication related to flow-diverter treatment, occurring in about 3–5% of cases and more common in posterior rather than anterior circulation (Brinjikji et al., 2013; Chancellor et al., 2020). Other complications include stent occlusion or in-stent stenosis after flow-diverter treatment, which has been reported at between 10% and 27%, with most being asymptomatic and occurring in small vessels <2.5 mm (Martínez-Galdámez et al., 2015; Zhou et al., 2017). The size of an IA (>10 mm) significantly correlates with major complications (death, hemorrhagic and ischemic stroke) after FD treatment (Bhatia et al., 2019; Brinjikji et al., 2013).

The use of flow diverters for acutely ruptured IAs in the setting of aSAH is controversial due to lack of evidence and high complication rates. Furthermore, inconsistent results have been reported on favourable neurological outcomes, ranging between 27% and 72% (Maus et al., 2018; Rouchaud et al., 2015; ten Brinck et al., 2020). In a recent meta-analysis and prospective observational study, the overall complication rate was reported at 31% and 45%, respectively (ten Brinck et al., 2020; Zhou et al., 2017) The risks of the treatment are more evident for ruptured

IAs in posterior circulation and when a higher number of FDs are used (Cagnazzo et al., 2018). The necessity of DAPT in the setting of aSAH likely increases the risk of complications in flow-diverter treatment. In a study by Manning et al., the new-generation PED with shield technology was tested using only Aspirin. Although the cohort was small (n=12), the overall morbidity and mortality rates were both 14% (Manning et al., 2019). The aim of treatment for ruptured IAs is to reduce the rebleeding rate. In the literature, rebleeding rates have been reported between 2% and 5% (Cagnazzo et al., 2018; Rouchaud et al., 2015). Although the rate of morbidity and mortality are significantly higher with flow-diverter treatment than simple coiling, flow diverters provide significantly high rates, over 90%, of occlusion for ruptured IAs (Cagnazzo et al., 2018; Rouchaud et al., 2015; ten Brinck et al., 2020).



**Figure 2.** Simplified schematic of the therapeutic mechanism of flow diversion treatment for aneurysms. (I) An aneurysm is (II) treated by implantation of a flow diverter, which reduces flow activity within the aneurysm and (III) promotes clot formation within the aneurysm over hours to days; concurrently, a new arterial lining, called neointima, starts growing over the device. (IV) Over weeks to months, the vessel remodels itself by resorbing the aneurysm along with completion of neointimal coverage of the device.

In 2008, the FDA approved the PED for the treatment of large or giant intracranial aneurysms from the petrous segment of the internal carotid artery to the hypophysial segment. Since then, the indications, both on- and off-label, of flow diverters has expanded. Several studies have been published on the use of flow diverters for small aneurysms, bifurcation aneurysms, and recurrent aneurysms (Limbucci et al., 2020). In a meta-analysis including over 500 distal aneurysms, a procedure success rate of 96% and an acceptable rate of morbidity and mortality were reported (Yan et al., 2018). The topic of recurrent aneurysms after coiling was specifically evaluated in

some retrospective series. Overall, the complete occlusion rate ranged from 60.7% to 100%, and the cumulative complete/near-complete rate ranged from 82.1% to 100%, confirming the efficacy of flow diverters in previously coiled aneurysms (Dornbos et al., 2017; Kühn et al., 2017). The endovascular treatment of wide-necked bifurcation aneurysms with assisted or unassisted coiling can be challenging, whereas flow-diverter placement in bifurcation may be technically easier. However, there is an unneglectable risk of ischemic stroke due to the jailing of the covered branches. As Cagnazzo et al. showed in their studies, including 12 studies evaluating 244 aneurysms, the complete/near-complete occlusion was found in 78.7% of patients and was less common in bifurcation than prebifurcation. However, the treatment of the middle cerebral artery carries a 21% rate of complications—with a 10.3% risk of permanent deficits (Cagnazzo et al., 2017). PREMIER was a prospective, single-arm multicenter US study evaluating the use of PED in the treatment of unruptured small aneurysms (Hanel et al., 2020). Most of the unruptured aneurysms treated in the PREMIER trial were <7 mm. Complete aneurysm occlusion was achieved in 81.9% of subjects at one year. The combined major stroke and death rate was 2.1% (Hanel et al., 2020). With these promising results in terms of safety and efficacy, the continually evolving flow-diverter treatment has become a cornerstone in many types of IAs that were once difficult to treat or untreatable. Increased periprocedural safety and the steady expansion of treatment targets now include small, recurrent, and even bifurcation aneurysms.

Regardless of the many advantages in terms of mechanical aspects, high metal surface still poses a risk for early and late thromboembolic complications. Low thrombogenic flow diverters like the p64 (Phenox) and Pipeline flex with Shield technology (Medtronic) are available in the market. The data on low-thrombogenic flow diverters for which dual-antiplatelet therapy is claimed to be not necessary are limited, mostly consisting of small case series. Therefore, large, preferably progressive, studies are necessary to change current practices (Lobsien et al., 2021; Manning et al., 2019). The future of flow diverters, based on preliminary studies, could even be bioabsorbable and aneurysm specific (Ding et al., 2021; Jamshidi et al., 2020). Future technological maturation, including surface modifications and a lower profile will likely extend treatment boundaries, on-label and otherwise, with a consequent need for high-quality clinical data to rigorously evaluate expanded use.

### 2.8.3.2 Intrasaccular flow disruption

Since the Guglielmi detachable coiling system was introduced, with help from developing technology, endovascular treatment has become amenable for most IAs. Effective treatment with simple coiling is not always possible, especially for complex aneurysms. Flow diverters are definitive treatment choices for side-wall

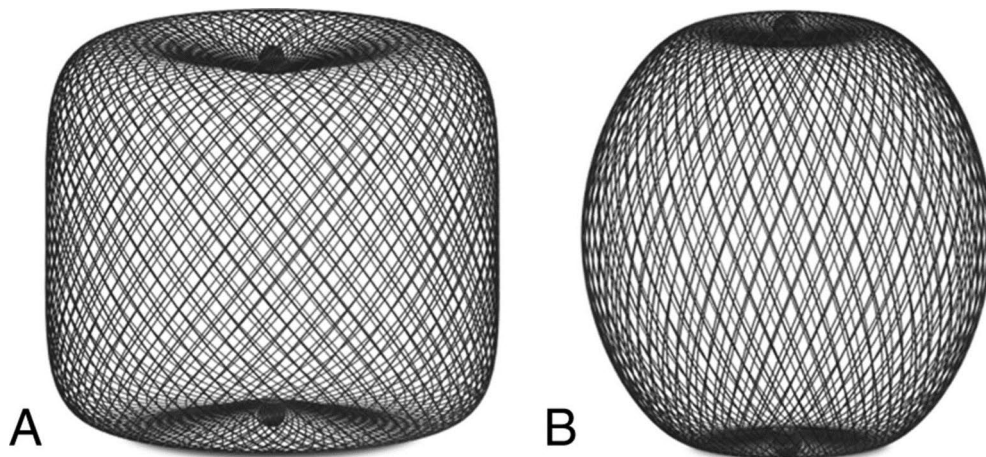
aneurysms and their indication for bifurcation aneurysms is off-label. Bifurcation aneurysms compromise almost 80% of IAs (Backes et al., 2014). The idea behind intrasaccular flow disruption is like that seen in the sac of an IA after flow-diverter treatment. Structurally, intrasaccular flow disruptors are constructed as braided wire mesh in different shapes. The device is deployed in the sack of an IA. Over time, endothelial growth at the neck of an IA causes complete occlusion. These devices are optimal for wide-necked bifurcation aneurysms. These devices do not require antithrombotic medication since they are placed in the sack of an IA. Several intrasaccular devices have been developed, including the Woven EndoBridge (WEB) device (Microvention, Aliso Viejo, California, USA), Luna Aneurysm Embolization System (LUNA AES; Medtronic, Irvine, California, USA), Medina Embolic Device (MED; Medtronic), and Contour Neurovascular System (Cerus Endovascular, Fremont, California, USA). Only the WEB has been approved by European and North American authorities and studied in terms of safety and efficacy.

The WEB was developed to treat wide-necked bifurcation aneurysms. The structure of the WEB consists of self-expandable and retrievable nitinol braided mesh. The WEB has been available since 2011 and recently received FDA approval for wide-neck bifurcation aneurysms. The WEB has developed progressively since its introduction. The first-generation WEB-DL (dual layer) has been replaced with the WEB-SL (single layer) and WEB-SLS (single layer sphere). The new-generation WEB devices have advantages in terms of easy trackability and control over previous generations. Therefore, the smallest aneurysm amenable to WEB treatment must be at least 3 mm wide and 3.5–4 mm tall to accommodate this device. The largest available WEB is the 11 SLS, which is 11 mm x 9.6 mm and can be used to treat aneurysms measuring 9–10 mm in width and 9.5–10.5 mm in height. The lower profile WEB 17 system is currently available in Europe and Australia. The WEB 17 SL system is available in diameters ranging from 3 x 2 mm to 7 x 5 mm. The WEB 17 SLS (Single-Layer Sphere) system is available in diameters of 4–7 mm. Thus, the 17 SLS system can be used to treat smaller aneurysms. In addition, since the devices themselves are more flexible and are delivered through the lower profile VIA-17 microcatheter, aneurysm access and WEB device deployment are often considerably easier. The hemodynamic effects of the WEB have not been widely studied. However, in a recent study by Gölitz et al., they found that the WEB significantly altered—almost as significantly as a flow diverter—the intra-aneurysmal flow, causing disruption more outflow than inflow (Gölitz et al., 2020).

The WEB intervention does not significantly differ from any endovascular intervention for intracranial aneurysms. The WEB intervention is done via triaxial femoral or radial access. After 3-D rotation angiography is captured, the next step is sizing, which is the most crucial part of WEB interventions. Treating physicians should measure the aneurysm to determine the diameter, height, and neck width of

the aneurysm in at least two orthogonal projections. The WEB device is delivered through a VIA microcatheter according to the manufacturer's guidelines.

The WEB device has been studied more profoundly, by a far margin, than other intrasaccular devices in several prospective and good clinical-practice studies. The WEB has been found to be effective in providing sufficient rates of adequate occlusion for challenging IAs. In the cumulative results of three European studies, a total of 153 aneurysms were included. Pierot et al. reported radiological outcomes at one year as follows: complete occlusion in 52.9%, neck remnant in 26.1%, and aneurysm remnant in 20.9%. Therefore, the adequate occlusion rate at one year was 78%, which was in line with the results of the WEB-IT (84.6%) study (Arthur et al., 2019; Pierot et al., 2018). Furthermore, the rates of adequate occlusion were 81% and 83.6% at two years and three years, respectively (Pierot et al., 2021; Pierot, Moret, et al., 2020). Even though almost half of the patient's loss to follow-up at three years, the proportion of adequately occluded IAs slightly increased. Pierot et al. concluded that aneurysm occlusion after WEB treatment is stable (Pierot et al., 2021). In addition to efficacy, the morbidity and mortality associated with the WEB has shown to be comparable to or almost as low as those of simple coiling. In the cumulative population of the three European Good Clinical Practice studies, the mortality at one month was 0.0%, with morbidity of 3.0% at one year (Pierot et al., 2018). Similar results regarding the safety of the WEB—a one-month mortality of 0.0% and morbidity of 0.7—were reported in the WEB-IT study (Fiorella et al., 2017). In a recent meta-analysis including 949 patients, cumulative morbidity was 2.8% and mortality was 0.9% (S. van Rooij et al., 2020). The most common complication of WEB treatment is thromboembolic events, with a rate of 0.7% for major stroke and 5% for minor stroke (Fiorella et al., 2017; Pierot et al., 2015). In several series including unruptured IAs, no rupture was observed after the WEB treatment. However, the rate of intraoperative rupture was 6% for both ruptured and unruptured IAs (Asnafi et al., 2016). In the largest series to date investigating 153 aneurysms treated with WEB, no spontaneous rupture occurred during the three-year study period (Pierot et al., 2018, 2021; Pierot, Moret, et al., 2020). WEB shape modification, a >5% decrease in height of the WEB post-treatment, was first described by Cognard et al. (Cognard & Januel, 2015). WEB shape modification was thought to be associated with inadequate radiological outcomes. Caroff et al., investigating outcomes of 63 IAs treated with WEB, found that web shape modification was more common in long-term follow-up (mean: 15.5 months); however, no statistically significant association was found between inadequate outcomes and web shape modification (Caroff et al., 2021).



**Figure 3.** WEB-SL device. A, The barrel-shaped WEB-SL. B, The spheric WEB-SLS.

The re-treatment rate after initial WEB treatment is about 11% (Essibayi et al., 2021; Pierot et al., 2021); considering the complexity of IAs and the learning curve, this rate is comparable to other conventional methods like simple coiling or SAC (Pierot et al., 2021). The treatment methods for recurrence after WEB treatment are flow diverting, SAC, and clipping (Pierot et al., 2019). The biggest advantage of the WEB is that antiplatelet therapy is not necessary since the WEB is an intrasaccular device. That said, in the treatment of ruptured wide-necked intracranial aneurysms, treating physicians have an alternative to SAC (Goyal et al., 2020). The results regarding protection from rebleeding after WEB treatment are promising. In the CLARYS analysis, investigating only ruptured IAs treated with the WEB, at one-month follow-up, the rate of rebleeding was 0.0% (Spelle et al., 2021). In a recent meta-analysis, Essibayi et al. reported a 1.1% rate of late rebleeding (Essibayi et al., 2021). A 13% rate of the perioperative complication rare was reported for ruptured IAs. Aneurysm- and patient-related factors predicting adequate occlusion after WEB treatment have been reported. Regular shape, thrombosis in aneurysm sack, and the height (>9 mm) and weight (>10mm) of an IA are aneurysm-related factors predicting radiological outcomes (Cagnazzo et al., 2019; Kabbasch, Goertz, Siebert, Herzberg, Borggreffe, Dorn, et al., 2019). No patient-related factors were predictive for aneurysm occlusion after WEB treatment (Cagnazzo et al., 2019). In addition to ruptured and unruptured IAs, the WEB device has been used in the treatment of recurrent IAs. In these studies, the adequate occlusion rate was between 64% and 73%, with no mortality and an 11% rate of complications (Gawlitza et al., 2018; Kabbasch, Goertz, Siebert, Herzberg, Borggreffe, Krischek, Dorn, et al., 2019; S. van Rooij et al., 2019)..

The LUNA AES is a self-expanding, mechanically detachable ovoid intrasaccular flow-disruption device. It is made from a double layer of 72 nitinol 25-

µm wire mesh (total of 144 wires) secured at both the proximal and distal ends. In a prospective study, the safety and efficacy of LUNA AES were assessed. Most of these aneurysms were unruptured and showed an adequate occlusion rate of 79%. Interestingly, there were no periprocedural complications directly attributed to the LUNA device. The rates of thromboembolic events (3.6%) were comparable to those seen in WEB studies. Furthermore, none of the LUNA AES-treated aneurysms re-bled during the 36-month follow-up period (Piotin et al., 2018).

The Contour (CERUS Endovascular, Fremont, USA) is constructed from nitinol micro-braided mesh available in a range of sizes applicable to both small- and medium-sized aneurysms (Bhogal et al., 2019). The device's effects consist of a combination of flow diversion at the neck by reconstructing the bifurcation and flow disruption within the aneurysm, avoiding manipulation of the fragile dome (Bhogal et al., 2019). A small series of 11 patients treated with the Contour device showed complete occlusion rates of 55.6% after one year, with all patients showing adequate occlusion rates (Akhunbay-Fudge et al., 2020). In other case series including only three patients, no major morbidity or mortality were reported; additionally, two IAs were completely occluded (Bhogal et al., 2021). Initial results are promising, although larger case numbers and longer follow-ups are necessary to draw further conclusions on the utility and risk profile of this new device.

Intrasaccular flow diversion continues to evolve at a rapid pace. Newer devices and advances in technology will hopefully allow for safer and more robust aneurysm occlusion. Although early results from the Contour and LUNA AES are promising, longer term studies are required. Long-term follow-up data at two, three, and five years are available for the WEB. The WEB device is an important tool for the treatment of wide-necked bifurcation IAs, particularly in patients for whom surgical clipping carries high risks and in patients with contraindications to antiplatelet therapies.

## 2.9 The follow-up of intracranial aneurysms

There are no international guidelines for the management of incidental IAs. However, follow-up imaging is recommended to patients for whom surgical or endovascular treatment could be suitable if their IA grows significantly (Thompson et al., 2015). Such imaging follow-up is typically accomplished with either CTA or MRA, performed annually at first and then at more protracted intervals if the aneurysm has remained stable for a long period; however, an optimal follow-up strategy has not yet been defined (Thompson et al., 2015). Imaging follow-up for an incidental IA at Turku University Hospital includes a routine MRA at one year after initial diagnosis and thereafter more seldomly with either MRA or CTA until five years after the initial imaging for patients <65 years.

Post-treatment surveillance imaging of intracranial aneurysms is determined by modality, local standard of care, and provider experience. No guidelines for follow-up imaging after treatment of intracranial aneurysms currently exist. The imaging studies commonly used to monitor aneurysms are CTA, MRA, and DSA. Over the last two decades, non-invasive angiographic imaging modalities, such as CTA and MRA, have greatly improved the detection and evaluation of cerebral aneurysms. DSA is a gold standard imaging modality for post-treatment follow-up; however, it is invasive and expensive. Shortcomings of the non-invasive imaging modalities are the presence of artefacts due to aneurysm clips, coils, and stents, including flow diverters and intrasaccular devices. The rationale behind post-treatment surveillance is detecting and evaluating recurrence, enlargement of remnants, and a de novo aneurysms.

Historically, the microsurgical clipping of intracranial aneurysms was thought to be extremely durable with low recurrence rates. Typically, the follow-up of a clipped-aneurysm starts in the operation room with indocyanine green video angiography (ICG-VA), in which an intravenous bolus of indocyanine green is given and then detected using a near-infrared filter on the operating microscope. This is as a useful tool in microsurgical clipping. Despite adequate intraoperative occlusion, the rate of aneurysm recurrence after clipping might be higher, as high as 10%, than commonly thought, depending on duration of follow-up and imaging modality (Thornton et al., 2000). Furthermore, “dog ear,” the remnants can enlarge in as many as 25% of cases, while broad-based residuals enlarge in as much as 75% of cases. Therefore, follow-up imaging for clipped aneurysms should be conducted to rule out significant recurrence for aneurysms that have a known residual and to evaluate for de novo aneurysms, irrespective of how well the index aneurysm was clipped. In most instances, CTA is sufficient; however, for patients in whom retreatment may be considered, DSA is often the preferred modality.

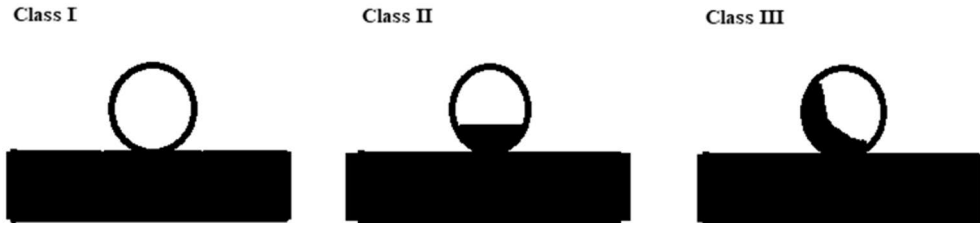
The high recurrence rate, as high as 20%, after endovascular treatments gives rise to an obvious need for post-treatment follow-up. The imaging modality and the frequency and duration of the follow-up depend on the endovascular treatment modality as well as institutional guidelines. In a large multicenter study, Ferns et al. showed that 22 of 400 patients with 440 aneurysms, within 10 years of time 11 simply coiled (2.5%) recurred, 9 of which had previously ruptured (Ferns et al., 2009, 2011). DSA is the imaging modality of choice for the short-term (6–12 months after initial treatment) follow-up of endovascularly treated aneurysms. MRA of varying techniques has become routine in the late follow-up of intracranial aneurysms. TOF-MRA is sufficient resolution for most aneurysms treated with simple coiling or WEB to detect most clinically meaningful recurrences that would have been otherwise seen on DSA with a sensitivity and specificity over 90% (Crobeddu et al., 2013; Timsit et al., 2016). The contrast-enhanced MRA, while only



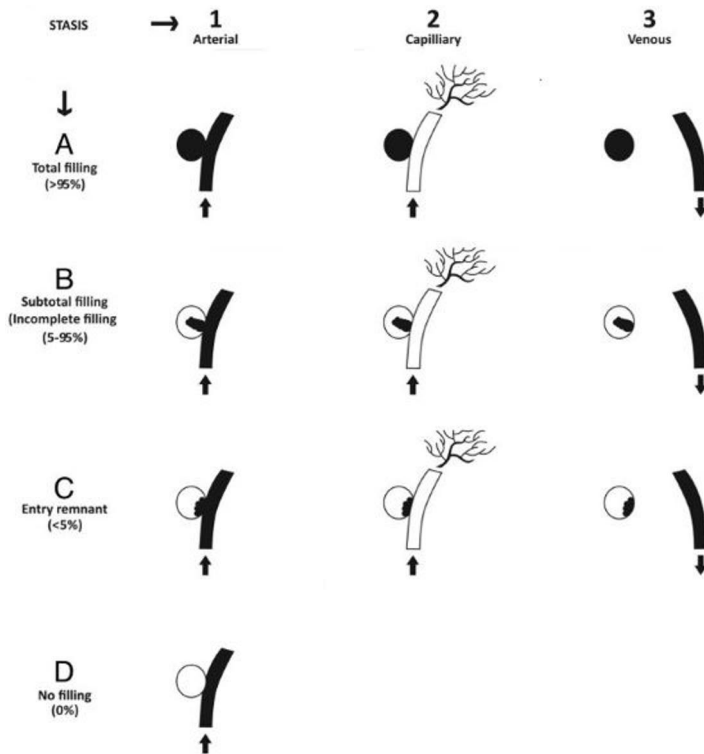
slightly better in terms of sensitivity and specificity relative to the TOF-MRA for coiling cases, is much better for detecting recurrent aneurysms when laser-cut stents or flow diverters are used (Ahmed et al., 2019; Xiang et al., 2021). At our institution, for aneurysms treated endovascularly, we typically perform follow-up DSA at six months after treatment. If the endovascularly treated aneurysm is completely or near-completely occluded at the six-month follow-up visit, we perform a follow-up MRA at two years after treatment. Depending on patient-related factors, such as age and comorbidities, the overall duration of imaging follow-up is five years after endovascular treatment. For aneurysms treated with microsurgery, a follow-up with DSA or CTA at three to six months, depending on intraoperative ICG-VA and surgeons' preferences, is performed. Most of the clipped aneurysms do not receive follow-up visits after three to six months.

## 2.10 The assessment of radiological outcomes

Several scales have been proposed for reporting the radiological outcomes of intracranial aneurysms after any given treatment. Angiographic outcomes of conventional aneurysm coiling are generally reported using the three-point scale by Roy and Raymond, where aneurysms are designated as complete occlusion, residual neck, or residual aneurysm (Roy et al., 2001). Although the Raymond–Roy occlusion classification (RR) is most often used, Mascitelli et al. have proposed a modified RR, because IAs reported as having a RR3 outcome do not necessarily occlude over time. In the Modified RR, Mascitelli et al. categorized RR3 to RR3a (contrast filing within coils) and RR3b (contrast filing between coils and aneurysm wall). Of these, according to their suggestion and observation, RR3a are more likely to occlude over time, whereas RR3b may tend to grove and rupture (Mascitelli et al., 2015). After the new endovascular devices for IAs were introduced and used, RR was not applicable for IAs treated with flow diverters. The O'Kelly–Moratta classification was proposed to assess radiological outcomes of IAs treated with flow diverters (O'Kelly et al., 2010). In this classification, each IA is assigned a grade according to the initial degree of filling (A, B, C, D) and the degree of stasis (1, 2, 3) observed through the angiographic phases (arterial, capillary, venous). Although Caroff et al. proposed a new occlusion classification for IAs treated with WEBs (Caroff et al., 2015), the three point-scale classification (RR) is used in several studies reporting radiological outcomes after the advent of the WEB (Arthur et al., 2019; Pierot et al., 2015).



**Figure 4.** Raymond Roy Classification for assessment of aneurysm occlusion after endovascular treatment. Class I, complete occlusion; Class II residual neck; Class III, aneurysm recurrence.



**Figure 5.** O'Kelly Marotta angiographic grading scale for assessment of aneurysms treated with flow-diverting stents. Intracranial aneurysms are assigned grades on the basis of the amount of contrast filling of the lumen (filling grades, A, B, C, D) and how long contrast persists in the lumen with respect to angiographic phase (stasis grades 1, 2, 3).

## 3 Aims

1. To evaluate feasibility and safety of the Woven EndoBridge as a contemporary alternative treatment for conventional endovascular methods in the treatment of the wide-necked recurrent intracranial aneurysms.
2. To evaluate safety and short-term radiological outcomes of patients treated with the new generation Surpass Evolve Flow Diverter.
3. To evaluate complications, clinical, and radiological outcomes of patients treated with flow diverters for acutely ruptured intracranial aneurysms.
4. To evaluate short- and mid-term radiological and clinical outcomes of patients treated with the Woven EndoBridge. Furthermore, to find out patient, and aneurysm related factors influencing radiological outcomes.

## 4 Materials and Methods

### 4.1 Study design and patients

The study I and II were conducted in collaboration with Helsinki University Hospital (I) and Edinburg University Hospital (II). The study III was a multi-center nationwide, and all Finnish University Hospitals (Turku University Hospital, Helsinki University Hospital, Tampere University Hospital, Oulu University Hospital and Kuopio University Hospital) participated to this study. The study IV was single centre (Turku University Hospital).

#### 4.1.1 The treatment of recurrent intracranial aneurysms with the Woven EndoBridge (I)

The study consists of patients ( $n = 22$ ) treated with WEB for their wide-necked (neck  $\geq 4$  mm or dome-to-neck ratio  $< 2$ ) recurrent IAs ( $n = 23$ ) between 2014 and 2020. The study cohort included both ruptured and unruptured IAs. The data regarding to patients, aneurysms and treatments were collected from digital in-hospital database. All treatment options including SAC, simple coiling and flow diversion for the recurrent IAs were discussed by multidisciplinary teams. It is considered as an advantage that WEB treatment doesn't require DAPT.

#### 4.1.2 The flow diversion with the new Surpass Evolve (II)

26 patients with 27 IAs were treated with the new Surpass Evolve flow diverter between May 2019 and June 2020 for their ruptured or unruptured at Turku University and Helsinki University Hospital. The flow diverter treatment was chosen in respect to morphology (blister-like, dissecting, or fusiform) and location (sidewall) of IAs. The decisions on the treatment were taken by multidisciplinary team. The data were collected retrospectively from both hospitals' aneurysm registry.

### 4.1.3 The treatment of acutely ruptured intracranial aneurysms with flow diverters (III)

In this nationwide retrospective study, the data were collected from in-hospital aneurysm registry. All patients treated with FDs for their acutely ruptured IAs between January 2012 and December 2019 included in the study. The cohort included 110 patients. Decisions on FD treatment were made at the discretion of the participating centers. The FD treatment was chosen as a last resort option by multidisciplinary team.

### 4.1.4 The Woven Endobridge for naïve intracranial aneurysms (IV)

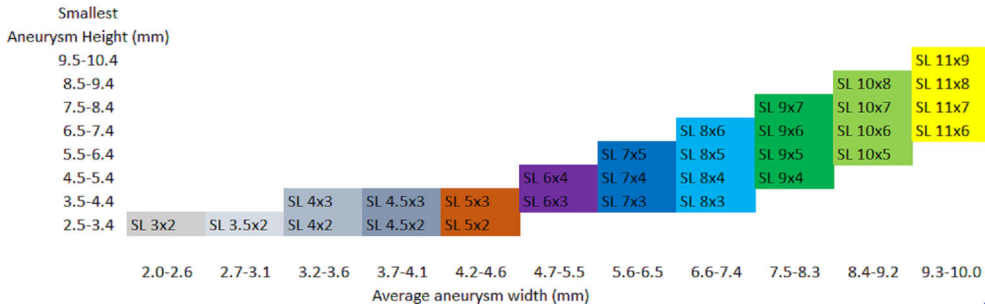
The study is a retrospective observational on consecutive patients who underwent the WEB procedure. The patients treated with the WEB for their recurrent IAs and patients without follow-up imaging were excluded. The WEB was chosen over other treatments such as simple coiling, SAC or microsurgery based on location and size of IAs along with the width of the neck. Furthermore, the WEB treatment doesn't necessarily need the DAPT after the treatment.

## 4.2 Endovascular treatment

### 4.2.1 The WEB treatment (I, IV)

All endovascular procedures were performed under general anesthesia thru a femoral or radial access. The appropriate WEB size was selected according to the IA width and height as measured on two-dimensional, particularly for recurrent IAs, and three-dimensional DSA images for naïve IAs. Implant sizes were chosen to be oversized according to the manufacturer's guidelines. The WEB was delivered through the dedicated VIA microcatheter. The use of additional devices was left to the neurointerventionalist's discretion. An intracranial self-expandible braided stent was implanted if WEB protrusion occurred, and adjunctive coiling performed to provide adequate occlusion of the recurrent IA. If adjunctive devices were used, the WEB was used to seal the aneurysm neck off from the parent vessel in all cases. All interventions were performed after systemic administration of heparin with doses targeting to double the activated clotting time (ACT) from the baseline. Patients treated at Edinburgh for recurrent IAs were loaded with Aspirin and Clopidogrel prior to embolization in case of a bail-out stent or SAC (Study I). However, post-operatively DAPT was discontinued. If a stent is applied during treatment (Study I,

IV), after a loading dose of Aspirin and Clopidogrel, DAPT is typically maintained for a month, onwards Aspirin 100 mg per day for three to six months.



**Figure 6.** WEB-SLS (single later sphere) sizing chart.

#### 4.2.2 The Surpass Evolve flow diverter treatment (II)

Procedures were performed under general anesthesia via triaxial femoral or radial access under a bi-plane angiography unit. Parent artery measurements were obtained with the utmost precision by using 3D reconstructions and 2D working projections. The Surpass Evolve Flow Diverter were delivered thru an 0.027" microcatheter which was placed distal to the aneurysm. Adjunctive coils were placed according to operator preference. Correct FD wall apposition was confirmed with Dyna-CT. All patients received heparin during the interventions to double the ACT from the baseline. For elective cases Aspirin 100 mg per day and Clopidogrel 75 mg / Ticagrelor 10 mg per day were started 5 to 7 days prior to the flow diverter treatment. DAPT for patients presenting with aSAH from acutely ruptured IAs was Aspirin 500 mg i.v and Ticagrelor 30 mg through a nasogastric feeding tube. The platelet inhibition was tested with VerifyNow® (Accumetrics, San Diego, CA) and Multiplate-platelet adenosine diphosphate (MPADP) in all cases.

#### 4.2.3 The flow diverter treatment of acutely ruptured intracranial aneurysms (III)

All patients were treated under general anesthesia via a transfemoral arterial approach, using a biplane angiography suite. Following arterial access, intravenous heparin was administered in most of the patients to maintain ACT between 250 and 300 seconds. After standard angiographic projection, an intra-arterial 3D rotational angiogram was performed in all patients to determine the optimal working position with 3D reconstructions. A triaxial system was used in all cases to maximize support during forward loading of the system and to optimize flow diverter stent opening and

apposition. The following FDs were used in the study: Pipeline embolization device (PED; Medtronic, Minneapolis, MN), PEDs with shield technology (Medtronic, Minneapolis, MN), Surpass Streamline (Stryker Neurovascular, Fremont, CA), FRED (MicroVention, Tustin, CA), FRED JR (MicroVention, Tustin, CA), Derivo (Acandis, Pforzheim, Germany), Surpass Evolve (Stryker Neurovascular, Kalamazoo, MI), and SILK (Balt, Montmorency, France). Abciximab was the most used periprocedural antiaggregant with a bolus and infusion for 24 hours. All centers tested platelet function with Multiplate® (Roche Diagnostic, Mannheim, Germany) or VerifyNow® (Accumetrics, San Diego, CA) test. Multiplate-platelet adenosine diphosphate (MPADP) <30U and 60–200 P2Y12 reaction-units (PRU) were considered a sufficient response. The most used antiplatelet treatment was Aspirin 100 mg and Prasugrel 5 or 10 mg. Prasugrel or clopidogrel was continued for at least 3 to 6 months unless there was a life-threatening hemorrhage. A dose of 100 mg of aspirin per day was continued for at least 6 to 12 months. According to protocol regarding to antithrombotic medicine of one center, post-procedural low molecular weight heparin was used as a second antithrombotic medicine in addition to aspirin 100 mg. At most of the centers, the duration of DAPT was decided based on the first imaging follow-up.

## 4.3 Clinical and radiological assessments

### 4.3.1 The treatment of recurrent intracranial aneurysms with the Woven Endobridge (I)

The diameters including the neck size, width, height of recurrent IAs were determined using preoperative 3-D rotational angiography whereas preoperative thrombosis determined with MRA or CTA. The data related to pre- and postoperative functional outcomes of patients were collected from electronic patient files and reported as mRS. The duration of follow-up and intervals, both clinical and radiological, were dependent on each institution's protocols. DSA and/or MRA were used to assess radiological outcome which were reported according to Raymond and Roy Occlusion Criteria (RR). RR 1 and 2 were considered as adequate outcome whereas RR 3 was inadequate, thus as aneurysm recanalization. Any discrepancy related to radiological outcome were solved by a senior neurointerventionist. Immediate clinical outcomes as well as any symptomatic complications —ischemic, hemorrhagic, and other types—of patients were assessed pre- and post-operatively.

### 4.3.2 The flow diversion with the new Surpass Evolve (II)

The morphology and diameters of the IAs were determined with preoperative 3D-rotational angiography. All patients were observed for any adverse events after the procedure. All patients underwent post-operative DSA according to the institutional protocols. The patency of parent artery, in-stent-stenosis as well as position of the FD stent were assessed from post-operative DSAs after three to six months. All patients were scheduled for a clinical follow-up between 3 to 6 months after the intervention. Aneurysm occlusions were assessed and reported according to the OKM scale.

### 4.3.3 The treatment of acutely ruptured intracranial aneurysms with flow diverters (III)

The preoperative clinical status of the patients at the admission was reported according to WFNS Scale. The Fisher scores were obtained from NECTs at admission to the hospitals. The morphology and diameters of the aneurysms were determined from 3D-rotation angiography. Post-operative CT and MRA were used to detect the treatment related complications. Any post-operative ischemic and hemorrhagic events were considered as treatment related complications. The duration and intervals of imaging follow-up varied somewhat among the participating centers. The last available clinical outcomes were reported as mRS score, whereas the radiological outcomes of the IAs were reported according to OKM scale.

### 4.3.4 The Woven EndovBridge for naïve intracranial aneurysms (IV)

The data regarding to patients such as smoking, hypertension was obtained from electronic patient files. Baseline aneurysm characteristics were evaluated using DSA with 3D-rotational angiography datasets. Aneurysm width, height, and neck width were determined for all aneurysms. The dome-to-neck (D/N) ratio, aspect ratio, and width-to-height (W/H) ratio were calculated. The size of the aneurysm was defined as the maximum diameter of the aneurysm. The aneurysm shape was determined using volume-rendered images of 3D rotational angiography datasets. Thrombosis in the aneurysm sack were determined from preoperative MRA or CTA. The imaging modality for follow-ups (6- and 24 months) was mostly MRA. Anatomic and angiographic results were independently evaluated by neuroradiologists not directly involved in patient treatment. A senior interventional neuroradiologist solved discrepancies. Aneurysm occlusions were assessed according to RR Occlusion



Classification. RR 1 and 2 were considered as adequate outcome whereas RR 3 was inadequate.

## 4.4 Statistical analysis

All the studies have been carried out in co-operation with a data scientist, and the statistical analyses have been carried out using the SPSS (IBM inc, New York, USA) software. In general, P values  $<0.05$  have been the criteria for statistical significance using 95% confidence intervals. Categorical variables were presented as percentages and numbers whereas continuous variables are presented as mean or median with SD or range in all studies. In study IV, categorical variables were assessed with a chi-square test, whereas normally distributed continuous variables with a t-test and non-parametric variables with a Wilcoxon rank sum test. Normality of the data was assessed using Kolmogorov-Smirnov test and visual inspection. Univariate logistic regression was used to assess the predictive value of the factors in predicting favorable angiographic outcome and re-treatment both 6-month and again at 24-month follow-ups. Predictive factors with a p-value below 0.1 were then used in a multivariate logistic regression model. Multicollinearity between these factors was assessed and of the factors that had a correlation coefficient above 0.8, the one with the lower p-value was included in the final multivariate logistic regression analysis. All statistical analyses were performed with SAS version 9.4 (SAS Institute Inc, Cary, North Carolina, United States of America).

## 4.5 Ethical aspects

Local institutional review boards waived the need for formal consent for this retrospective registry study. The following study permissions were approved by the local institutional review boards: Turku University Hospital (T011/014/18), Tampere University Hospital (R16619), Kuopio University Hospital (166/2016), Oulu University Hospital (215/2018) and Helsinki University Hospital (HUS/125/2018). For the study I, The Academic and Clinical Central Office for Research and Development (ACCORD) for the University of Edinburgh and NHS Lothian approved data sharing.

# 5 Results

## 5.1 The treatment of recurrent intracranial aneurysms with the Woven Endobridge (I)

### 5.1.1 Patient, aneurysm, and intervention characteristics

Twenty-two patients (68% females, median age: 53 years) with twenty-three recurrent IAs were treated with the WEB. Seventy-eight percent of the IAs (n=18) had ruptured previously. All recurrent IAs were wide-necked (median width: 5 mm). 20 recurrent IAs was in anterior circulation and most common location was MCA. 17 IAs had been initially treated with simple coiling, 3 with WEB and 3 with microsurgical clipping. The median duration from the initial treatment to the treatment of recurrency was four years (range: 2-23 years). The intervention only with WEB was feasible in 87% of cases (n=20). However, adjunctive devices (coils or stents) were used in three recurrent (13%) IAs.

**Table 5.** The characteristics of recurrent aneurysms (Study I).

	<b>Location</b>	<b>Initial treatment</b>	<b>Size of recurrence</b>
1	Basilar tip	Clipping	15x19 mm
2	MCA/MCA	Coiling / Coiling	9x11 mm / 10x9 mm
3	MCA	Clipping	5x5 mm
4	MCA	Coiling	9x10 mm
5	MCA	Coiling	3.5x3 mm
6	MCA	Coiling	8x12 mm
7	MCA	WEB	10x8 mm
8	MCA	Coiling	4x4 mm
9	ACom	Clipping	4x2 mm
10	ACom	WEB	4x4 mm
11	MCA	WEB	4.5x6 mm
12	PCom	Coiling	5.7x3.1 mm
13	Basilar tip	Coiling	5.9x4.3 mm
14	Acom	Coiling	7.2x5.3 mm

	<b>Location</b>	<b>Initial treatment</b>	<b>Size of recurrence</b>
15	Acom	Coiling	8.1x4.3 mm
16	Pericallosal	Coiling	2.4x4.9 mm
17	MCA	Coiling	3.8x3.5 mm
18	Acom	Coiling	5.5x3.8 mm
19	Basilar tip	Coiling	5.3x4.4 mm
20	Pericallosal	Coiling	4.9x3.8 mm
21	Acom	Coiling	4.4x2.5mm
22	Acom	Coiling	3.1x3.2mm

Acom, anterior communicating artery; Pcom, posterior communicating artery; MCA, middle cerebral artery

### 5.1.2 Radiological Outcomes

The radiological follow-up data with the median duration of 24 months, were available for all cases. Twenty recurrent (87%) IAs showed adequate occlusion (RR I or II) at the last follow-up after the WEB treatment. Of these aneurysms, the radiological outcome of 12 recurrent IAs (52%) was RR class I, and eight recurrent IAs (35%) were RR class II. Recanalization (RR III) seen in three recurrent IAs. All recanalized IAs had partially thrombosed sack before the retreatment with WEB. Worsening from the adequate occlusion to inadequate occlusion hasn't been observed during follow-up.

### 5.1.3 Complications and Clinical Outcomes

A late (14 days after the intervention) intracranial hemorrhagic event occurred. Due to this, the functional outcome of the patient worsened from mRS score 1 to mRS score 2. No other post-operative change was detected in functional outcomes of patients. No bleeding or rebleeding of IAs or treatment related adverse effects were observed.

## 5.2 Flow diversion with the new Surpass Evolve (II)

### 5.2.1 Patient, aneurysm, and intervention characteristics

The study involved 29 patients (72% females) with the mean age of 55.5 years. Both unruptured (n=24) and ruptured (n=6) IAs were treated with the Surpass Evolve FD. The morphology of aneurysms was saccular (n=28) and fusiform (n=2). Most of the aneurysms were small <10 mm (n=20) and located in ICA (n=22). The deployment of FD was successful in all patients. In two cases, several flow diverters were used

in the treatment. In two cases coils were used to secure or initiate the thrombosis. No cases needed balloon angioplasty after the deployment of the FD.

### 5.2.2 Radiological outcomes

A total of 26 patients with 27 IAs were available for radiological follow-up. The DSA were performed to all cases as an initial follow-up imaging. A total of 21 IAs showed complete (OKM-D) or near complete (OKM-C) occlusion in the follow-up imaging. Mild (<50%) in-stent stenosis with tapering in distal end was seen in two cases.

### 5.2.3 Complications and clinical outcomes

Two patients presenting with acutely ruptured IAs died due to complications of aSAH. No intraoperative rupture of the IA occurred. An unruptured large IA located in ICA ruptured on the sixth day after flow diverter treatment without ancillary coils. Because of this event, the patient died. The rest of the elective cases showed no changes in neurological status.

## 5.3 The treatment of acutely ruptured intracranial aneurysms with flow diverters (III)

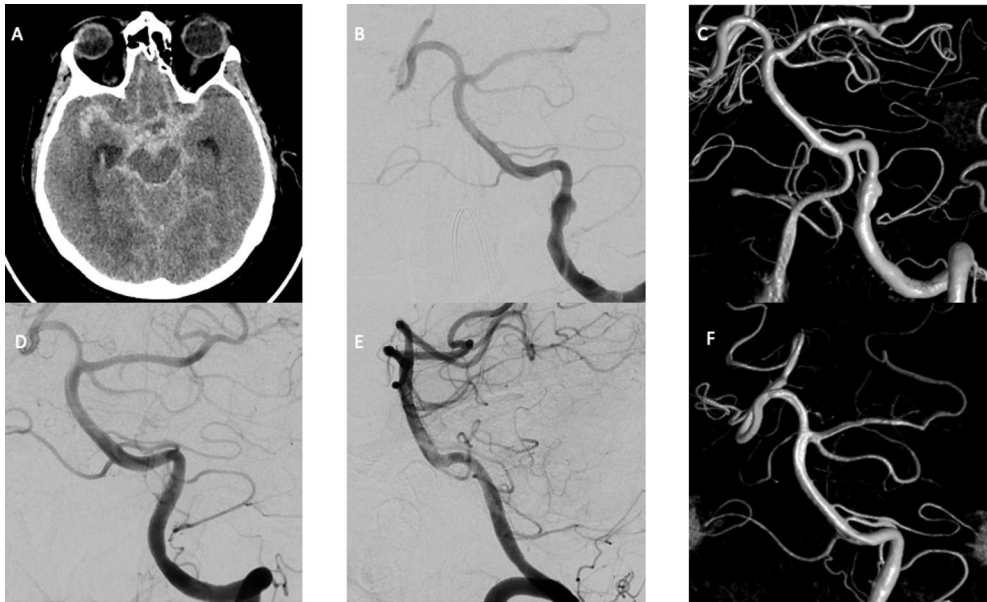
### 5.3.1 Patient, aneurysm, and intervention characteristics

One-hundred-ten patients (58% female) harboring 110 acutely ruptured IAs with a mean diameter of 4.8 mm (range: 2-25) were treated with FDs in the setting of aSAH. The mean age of patients was 55.7 years (range: 12-82). The most IAs were in anterior circulation (70%). The most common morphology of IAs was blister-like (n=47). PED with shield technology (Medtronic, Minneapolis, MN) was the most preferred flow diverter (n=62, 48%). Sixteen percent of aneurysms (n=18) were treated with multiple FDs, and in 5% of aneurysms (n=5) coils were used to secure the occlusion.

### 5.3.2 Radiological outcomes

The radiological data with a mean duration follow-up of 11 months from the last imaging follow-up were available from 80% (n=88). Of these, radiological outcomes of 55 patients were assessed with DSA, and remaining 33 patients were assessed either MRA or CTA. The complete (OKM-D) or near complete occlusion (OKM-C)

were observed in 90% of the IAs (n=79) whereas only one IA showed total filling after the treatment.



**Figure 7.** A NECT image of 62 years old female show diffuse aSAH (A). DSA and 3D-rotational image show a 6x7 mm ruptured fusiform aneurysm in the left vertebral artery (B, C). Aneurysm treated with a PED 4x20 mm. DSA and 3-D rotational image show complete occlusion of the IA and remodelling of the artery at 6 month-follow-up (D, E, F).

### 5.3.3 Complications and clinical outcomes

No intraoperative rupture occurred. However, 3% (n=3) of rebleeding rate was observed. Of these, two rebleeding occurred within 14 days after the FD treatment. None of the rebled aneurysms had adjunctive coiling in the initial treatment. A total of 45% of patients (n=49) had treatment related complications. The rate of hemorrhagic intracranial complications was 40% (n=44) whereas ischemic intracranial complications were detected in a total of 29% patients (n=32). Among the patients with ischemic and hemorrhagic complications, unfavorable outcome (mRS 3-6) was seen in 40% (n=20).

The follow-up data (mean: 8 months, range: 1-60 months) were available for 93% of patients (n=102). 73 percent of patients (n=74) had favorable (mRS 0-2) outcome. The overall mortality and treatment related mortality rates were 18% (n=18) and 5% (n=5), respectively

**Table 6.** Intracranial complications after the flow diverter treatment (Study III).

Re-bleeding	3 (3%)
In-stent thrombosis	9 (8%)
Post-op ICH	19 (17%)
ICH due to an EVD placement	9 (8%)
ICH due to re-bleeding	3 (3%)
ICH due to a mechanical complication	1 (1%)
New idiopathic post-operative ICH	3 (3%)
Expansion of pre-operative ICH	4 (4%)
Post-op ICH	19 (17%)
Post-op IVH	25 (23%)
Ischemic stroke	32 (29%)

ICH, intracerebral haemorrhage, EVD, external ventricular drain; IVH, intraventricular haemorrhage.

## 5.4 The Woven EndoBridge for naïve intracranial aneurysms (IV)

### 5.4.1 Patient, aneurysm, and intervention characteristics

The data were available from 91 patients (62% female), with the mean age of 58.8 years, and 62 patients (58% female) with the mean age of 57.7 years, for 6-month and 24-month analysis, respectively. Twenty-eight patients were treated in the setting of acute aSAH. Three aneurysms (4.7%) were partially thrombosed. WEB-SL was used in all cases ( $n = 91$ ). Ancillary devices were used in 6 patients (6.5%); in three case coils, in three cases stents. The deployment of WEB device was successful in all cases. Depending on degree of WEB protrusion into a parent artery, Aspirin (100 mg/day) was started immediately and continued for up to six weeks. In cases which a braided intracranial stent was deployed, DAPT was initiated immediately with a bolus dose (Aspirin 500 mg and Prasugrel 30 or 60 mg) and continued (Aspirin 100 mg/day and Prasugrel 5-10 mg) for six months.

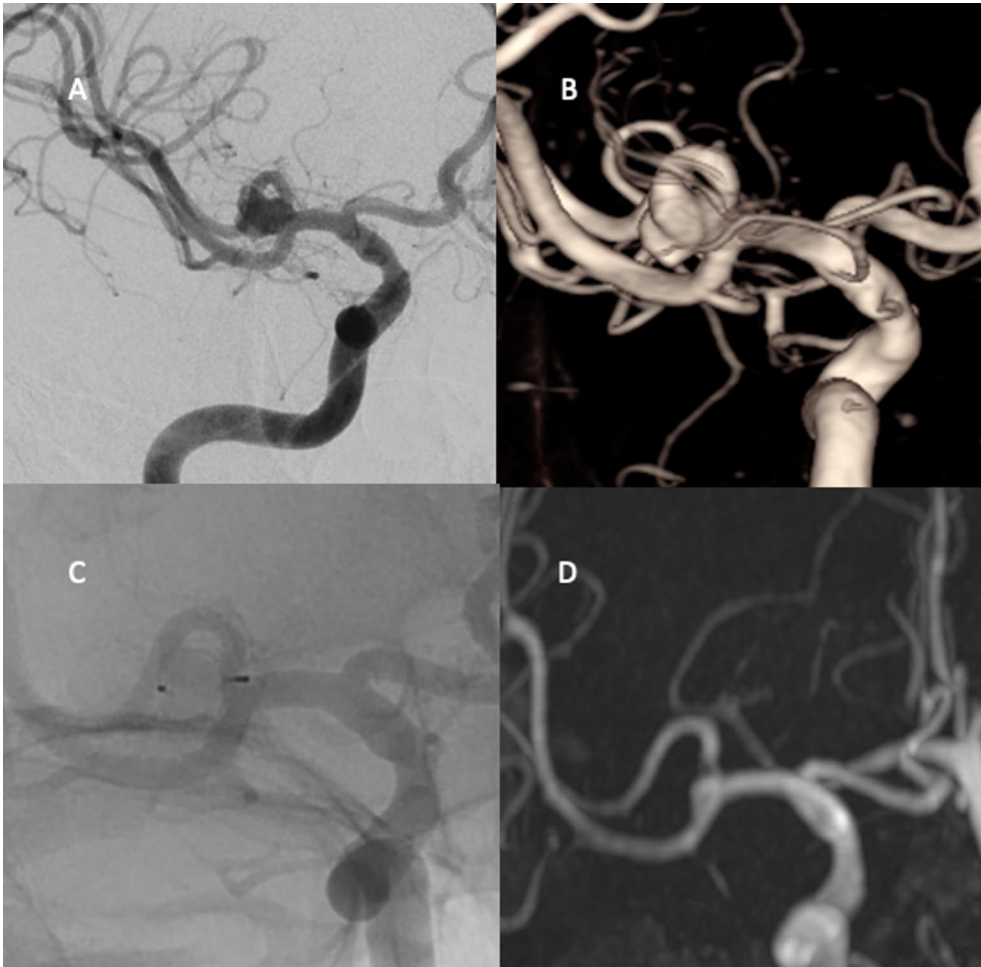
**Table 7.** Characteristics of the naïve aneurysms treated with WEB (Study IV).

	<b>6-month follow-up</b>	<b>24-month follow-up</b>
No. of aneurysms	91	62
Location of Aneurysm		
ICA	9 (10%)	6 (10%)
MCA	39 (43%)	26 (42%)
Acom	13 (14%)	5 (8%)
Basilar Tip	21 (23%)	17 (27%)
ACA	5 (5)	4 (6%)
Vertebrobasilar	5 (5%)	4 (6%)
Mean maximal diameter	7.9±2.8	8.0±2.9
Mean width	6.3±2.2	6.4±2.2
Mean height	6.8±2.7	6.9±2.6
Mean width of neck	4.6±1.3	4.7±1.3
Multi-lobular	23(25%)	16 (26%)
Partially thrombosed	3 (3%)	2 (3%)
Acutely ruptured	28(31%)	14 (23%)
Bifurcation	83(91%)	56 (90%)
Wide-necked	74(81%)	53 (85%)

ICA, internal carotid artery; MCA, middle cerebral artery; Acom, anterior communicating artery.

### 5.4.2 Radiological outcomes

At six-month follow-up complete aneurysm occlusion was achieved in 56 cases (62%), neck remnants in 25 (27%) and aneurysm remnants in 10 (11%). Hence, adequate occlusion was obtained in 89%. Similarly, at 24-month follow-up complete occlusion in 42 cases (68%), neck remnants in 14 (23%) and aneurysm remnants in 6 (9%), hence, adequate occlusion was 91%. The radiological outcomes of three aneurysms (5%) declined from adequate to inadequate between six- and 24-month follow-ups. Thirteen aneurysms (14%) were re-treated during the study period.



**Figure 8.** DSA and 3D-rotational image shows an unruptured irregular shaped MCA aneurysm (A, B). An intraoperative DSA image shows immediate adequate occlusion (C). TOF-MRA shows complete occlusion at 6month follow-up.

### 5.4.3 Factors affecting radiological outcome

None of the patient related factors such, as age or smoking status, was not associated with the radiological outcome. Neither ruptured aneurysm status, nor aneurysm location were not significantly associated with aneurysm occlusion. The width of the neck wasn't predictive for radiological outcomes. The height, width, and irregular shape of an IA were found to be predicting factors for adequate occlusion after the WEB treatment. Factors influencing radiological outcomes after the WEB treatment are summarized in table 7.



**Table 8.** Factors influencing radiological outcomes after the WEB treatment (Study IV).

	<b>6 months p-value</b>	<b>24 months p-value</b>
Height of aneurysm	>.05	.02
Width of aneurysm	>.05	.002
Aspect-ratio	>.05	.03
Dome-to-neck ratio	>.05	.04
Maximum diameter	>.05	.001
Acutely ruptured	>.05	>.05
Wide-necked	>.05	>.05
Lobular shaped	.01	.03

#### 5.4.4 Complications and clinical outcome

Neither intraoperative nor aSAH after the WEB treatment was not occurred. Treatment related morbidity was 4% (n=4), and mortality (consequences of an ipsilateral malign MCA territory infarct) was 1% (n=1). A favorable outcome (mRS  $\leq 2$ ) was achieved by 62 of 63 elective patients (99%). One patient died due to unrelated event (cancer) during the study period.

## 6 Discussion

### 6.1 The treatment of recurrent intracranial aneurysms with the Woven EndoBridge (I)

In our study including 23 IAs, we observed a better rate of adequate occlusion than in previous studies, as well as a lower recanalization rate. Twenty recurrent IAs (87%) showed adequate occlusion at the last follow-up, and three IAs (13%) showed recanalization. The adequate occlusion rate in our series can be considered satisfactory, especially with respect to the complexity of recurrent IAs. There are a few reports on the safety and efficacy of the WEB for recurrent IAs. The studies overall harbor 41 recurrent IAs (Gawlitza et al., 2018; Kabbasch, Goertz, Siebert, Herzberg, Borggrefe, Krischek, Dorn, et al., 2019; S. van Rooij et al., 2019). In the sum of the previous studies, the adequate occlusion rate of recurrent IAs treated with WEB was 71% (n=29), and the recanalization rate was 29% (n=12) (Gawlitza et al., 2018; Kabbasch, Goertz, Siebert, Herzberg, Borggrefe, Krischek, Dorn, et al., 2019; S. B. T. van Rooij et al., 2019). An intracranial hemorrhage two weeks after the treatment occurred in our study. No other treatment-related morbidity or mortality was observed in our study. The rate of adverse effects in our study was in line with other previous studies (Gawlitza et al., 2018; Kabbasch, Goertz, Siebert, Herzberg, Borggrefe, Krischek, Dorn, et al., 2019; S. van Rooij et al., 2019).

The microsurgery, simple coiling, as well as stent- and balloon-assisted coiling are conventional retreatment, whereas intraluminal flow diversion and intrasaccular flow disruption are contemporary retreatment methods. The simple coiling of recurrent aneurysms carries reasonable risk (1–3%) of permanent neurologic deficits; however, the failure rate—that is recanalization—cannot be neglected (Henkes et al., 2006). SAC can provide more durable radiologic outcomes for recurrent IAs, but the risk for unfavorable outcomes is reported to be as high as 10%. (Tähtinen et al., 2013). The indications of flow diversion have been expanded, including the treatment of aneurysm recanalization. Overall, the complete occlusion rate ranged from 60.7% to 100%, and the cumulative complete/near-complete rate ranged from 82.1% to 100%, confirming the efficacy of FD in previously coiled aneurysms (Chalouhi et al., 2014; Kühn et al., 2017). In contrast, The results of FD treatment for recurrence of previously stented aneurysms are not encouraging, with

occlusion rates ranging from 38% to 65% (Bender et al., 2018; Daou et al., 2016). Overall, FDs are feasible for both naïve and recurrent sidewall IAs but not for IAs located in bifurcations. Caroff et al. reported 43% of ischemic and 21% of procedure-related complications in FD treatment for MCA bifurcation aneurysms (Caroff et al., 2016). Apart from the challenges due to coil packing in the neck of recurrent IAs for clipping, microsurgery carries a 12% risk of poor outcome (Romani et al., 2011; Veznedaroglu et al., 2004).

The underlying reason for recanalization after WEB treatment in our study is likely thrombus in aneurysm sacks. All recurrent IAs (n=3) with partially thrombosed sack recanalized after the re-treatment with WEB. Kabbasch et al. found that thrombus in the aneurysm sack predicts recanalization after WEB treatment (Kabbasch, Goertz, Siebert, Herzberg, Borggreffe, Dorn, et al., 2019). Along with thrombosis in the aneurysm sack, other reasons for recanalization after retreatment can be growth of an IA and coil packing into the dome (Henkes et al., 2006).

## 6.2 Flow diversion with the new Surpass Evolve flow diverter (II)

FDs are robust devices for the treatment of IAs. Their safety and efficacy have been demonstrated in large and giant anterior circulation aneurysms, sidewall aneurysms of <12 mm, distal lesions, and selected ruptured aneurysms (Limbucci et al., 2020). The first-generation Surpass Streamline was the second FD that was approved for clinical use by the FDA after the SCENT trial (Meyers et al., 2019). The Surpass Evolve (SE) represents the next generation of the Surpass FD. SE has a lower profile while maintaining an important flow-diverting effect (Sadasivan & Fiorella, 2020). There are a few studies regarding the technical nuances and safety of the Surpass Evolve in the literature.

In our study, technical success was achieved in all cases (n=27), consistent with previous studies (Maus et al., 2021; Orru et al., 2020). As a preference of the operators, only one case received adjunctive coiling during the initial treatment. Although comparing the rates of adjunctive coiling between our study and previous reports is not appropriate because of the different morphology of the aneurysms and preferences of operators, overall, 19 of 69 IAs received adjunctive coiling in previous studies (Maus et al., 2021; Orru et al., 2020). The proper wall apposition, which predicts radiological outcomes, is crucial in FD treatments. Orru et al. reported a 28% rate of post-deployment angioplasty due to suboptimal wall apposition; however, in our study, no patient required angioplasty (Orru et al., 2020). Similarly, Maus et al. reported a very low rate (2%) of angioplasty after the deployment of SEs. As Orru et al. underlined in their study, the high rates probably reflect authors' extremely low threshold for performing angioplasty whenever suspecting

incomplete FD apposition on Dyna-CT, given the demonstrated role of malapposition in delayed aneurysm healing. Severe or complete in-stent stenosis can cause devastating neurologic symptoms after FD treatment. In our study, a 7% rate of mild stenosis was observed, and no severe or complete in-stent stenosis was observed at six months. On the contrary, Maus et al. reported one severe stenosis due to the tapering of SE, three mild stenosis, three complete occlusions of the parent artery in their series harboring 46 IA (Maus et al., 2021). The complete occlusion of the parent artery due to intimal hyperplasia after an FD treatment raises concern about the importance of testing platelet inhibition. In both studies, ours, and that by Maus et al, all patients were tested for platelet inhibition. In our study, aSAH occurred in one elective patient on the sixth day after treatment of a large aneurysm. The rate of aSAH after treatment with SE was 2% in the SCENT trial. In previous studies, no rupture of the target IAs occurred (Maus et al., 2021; Orru et al., 2020).

Flow diversion can be considered a curative treatment for IAs, as reported occlusion rates are between 90% and 95% (Brinjikji et al., 2013; Chancellor et al., 2020; Y.-L. Li et al., 2021). The rate of complete and near-complete occlusion of IAs treated with SEs in our study was in line with the previous report by Maus et al. (85% vs. 86%) (Maus et al., 2021). In direct comparison to the initial SE experience of previous studies, overall, our results are in conjunction with previous reports. One major thromboembolic event and one rupture of the target aneurysm were observed in the study by Orru et al. and in our study, respectively. However, it is worth mentioning again that the cohorts were too small and heterogeneous to allow for a distinct comparison between the two studies.

### 6.3 The treatment of acutely ruptured intracranial aneurysms with flow diverters (III)

The proportion of favorable functional (mRS  $\geq 2$ ) outcomes at last follow-up in our study was 73%, which was better than the results of a multicenter study by Ten Brinck (ten Brinck et al., 2020). A 93% rate of complete and near-complete occlusion were seen in IAs in our study, which was consistent with a recent study (ten Brinck et al., 2020).

Flow-diversion treatment has opened a new chapter in the treatment of intracranial aneurysms and is well established for unruptured IAs. The main reason for the early treatment of ruptured IAs is to prevent the catastrophic consequences of early rebleeding. FD treatment results in only partial immediate aneurysm occlusion, with delayed flow diversion leading to complete or nearly complete aneurysm occlusion over a period of months (Zhang et al., 2019). Although aneurysm occlusion after FD treatment occurs over time, the rate of rebleeding ranges between 2% to 5% (Cagnazzo et al., 2018; Madaelil et al., 2017). In our

study, rebleeding occurred in 3% of cases (n=3). Certain factors like the larger size of an IA and peri-operative anticoagulation are proposed to be associated with rebleeding (Cagnazzo et al., 2017; Manning et al., 2019; ten Brinck et al., 2020). Like Manning et.al reported, all cases with rebleeding were received low-molecular-weight-heparin in our study. We may conclude that the use of low-molecular-weight-heparin peri-operatively may be associated with rebleeding.

The treatment-related complications were seen in a total of 49 (45%) patients in our study. Contrary to the occlusion and rebleeding rates, the rates of overall complications ranged widely in the literature. Ten Brinck et al. reported a 45% rate of overall complications, whereas the overall complication rate was 8% in the study by Cohen et al. (Cohen et al., 2021; ten Brinck et al., 2020). The lack of precise guidelines leads to significant variations in anticoagulation and antiplatelet regimens and testing. Clopidogrel is the most-used antiplatelet medication in association with Aspirin. However, the proportion of non-responders to clopidogrel cannot be neglected. To decrease the rate of ischemic complications and in-stent thrombosis, it is essential to achieve sufficient platelet inhibition, which is confirmed with platelet function tests. However, the use of platelet function tests in reported studies varied somehow (Cohen et al., 2021; ten Brinck et al., 2020).

In our study, post-operative ICH were seen in 19 patients. Among these patients in almost half of them ICH occurred either revision or placement of an EVD. The need for DAPT in FD treatment for acutely ruptured IAs presents management challenges for patients. However, hemorrhagic complications can be further minimized with a low threshold for EVD insertion before the intervention, and thus before the administration of DAPT (Kung et al., 2011). Ischemic changes (both symptomatic and asymptomatic) were seen in 29% of patients (n=31). In a meta-analysis of 20 studies, the rate of ischemic complications was 8% (Cagnazzo et al., 2018). The noticeable differences in complication rates between our results and those in the literature, compared to small case series and meta-analyses, can be attributed to various factors. Furthermore, we requested that participating centers report both clinically silent and important complications during the total duration of follow-up instead of only peri-procedural complications. Additionally, in our series, we considered all reported ischemic strokes, except those attributed to DCI, as intervention related. Finally, it is highly likely that the “best case scenario” patients were selected for the included reports and then the meta-analyses. When comparing the complication rate associated with the use of FDs against other endovascular or surgical modalities for the treatment of ruptured aneurysms, it is essential to keep in mind that FDs are usually considered for the treatment of challenging aneurysms, where other modalities are deemed too risky or unfeasible.

## 6.4 The Woven EndoBridge for naïve intracranial aneurysms (IV)

Endovascular treatment has developed substantially since Guglielmi introduced detachable coils in 1991. Studies have shown that the effective treatment of more complex aneurysms with coils alone is often not technically possible. This has led to the use of balloon remodelling and SAC techniques, which have allowed for the treatment of wide-necked and complex aneurysms, and have provided better occlusion and lower recurrence rates (Henkes & Weber, 2015). Balloon remodeling and SAC can provide better radiological outcomes for wide-necked and complex IAs (Consoli et al., 2016) However, the necessity of using DAPT include the shortcomings of SAC, which can be linked to hemorrhagic complications. In a propensity score analysis by Kabbasch et al, SAC showed a higher overall complication rate than WEB treatment (21% vs. 12%) (Kabbasch, Goertz, Siebert, Herzberg, Borggreffe, Krischek, Stavrinou, et al., 2019).

The WEB has been a game-changer for not only unruptured but also ruptured wide-neck IAs. In our study, the WEB has yielded 89% (n=81) and 91% (n=56) adequate radiological outcomes at 6 and 24 months, respectively. The results of our study in terms of treatment complications and radiological outcomes at 6 and 24 months were consistent with previous studies, with no rupture or re-rupture during the follow-up period. The rate of adequate occlusion (RR 1–2) after the WEB was between 80% and 84% in WEB-CAST and WEB-IT studies at one year (Arthur et al., 2019; Pierot et al., 2015). Considering that the morphology of aneurysms typically treated with the WEB device is more complex than that of aneurysms treated by regular coiling, these occlusion rates appear promising. The low morbidity and mortality (4% and 1%, respectively) rates in our study were also consistent with previous studies (2-3%, 0%, respectively) (Arthur et al., 2019; Pierot et al., 2015).

In our study, we analysed several aneurysms- and patient-related factors that might affect radiological outcomes. Youssef et al. found an association between smoking and aneurysm recurrence after WEB treatment (Youssef et al., 2021). However, we were not able to confirm statistically any patient-related factors affecting radiological outcomes. This may be due to small size of cohort and low proportion of unfavorable radiological outcomes. Based on the results of our study, the treatment of large (>11 mm) and partially thrombosed aneurysms by WEB were associated with unfavorable occlusion rates. Furthermore, lobular shaped IAs are prone to inadequate occlusion after WEB treatment based on the results of our study. The higher and the larger an IA is, the less probable adequate occlusion is, as found in our analysis of 24-month follow-up radiological outcomes. In our study, there was no significant difference between ruptured and unruptured IAs in terms of occlusion rates. These findings were in accordance with previous studies (Cagnazzo et al., 2019; Kabbasch, Goertz, Siebert, Herzberg, Borggreffe, Dorn, et al., 2019). Contrary

to the study by Cagnazzo et al., we were not able to find an association between inadequate occlusion and the width of the neck or adjunctive coiling (Cagnazzo et al., 2019; Kabbasch, Goertz, Siebert, Herzberg, Borggreffe, Dorn, et al., 2019).

## 6.5 Study limitations and strengths

The major limitations of our study are its retrospective, single-arm design, and the lack of comparison groups. Due to the retrospective design of our study, some data on clinical and radiological follow-ups is missing, despite searching the nation-wide electronic patient file database (KANTA). Inconsistent use of antithrombotic medications for the WEB interventions, and unstructured management of antithrombotic medications peri- and post-operatively in FD treatment might have affected the complication rates. Furthermore, small size of cohorts (Studies I, II, and IV) may affect low rates of complications. Without routine post-operative MRI screening, it is impossible to know the rate of silent ischemic changes. Although most of the radiological follow-up data was based on the MRI studies, which were assessed by an independent neuroradiologist, the data from the DSA imaging was self-assessed.

Finally, the strength of this study is that it represents “real world experience.” Furthermore, the results of this study provide valuable insights into the contemporary endovascular treatment of aneurysms, and thus can help treating physicians in decision-making in daily practice

## 6.6 Future perspectives

The endovascular era has revolutionized the treatment of intracranial aneurysms. Intraluminal flow diversion is already considered a curative treatment for most challenging aneurysms. However, high metal coverage requires patients to remain life-long antiplatelet medications which are associated with ischemic and hemorrhagic complications. Bioabsorbable individualized flow diverters, on which there are a few experimental studies, will possibly replace current flow-diverter stents. The advantage of bioabsorbable stents over current flow-diverter stents is that anti-platelet medications could be temporary, not life-long. The research on intraluminal devices in the future will probably focus on low-thrombogenic and bioabsorbable flow-diverters. Furthermore, there will probably be some clinical trials on the single anti-platelet therapy for the intraluminal flow diversion. Intrasaccular flow disruption, given the procedure’s technically straightforward and efficient nature, is developing, and there will very likely be a progressive expansion of indications for intrasaccular flow disruption therapies to the extent that they will ultimately replace standard coiling in an increasing number of cases. The long-term

radiological results of the WEB will be studied in next couple of years. In the future, endovascular treatment will be more individualized, there could even be aneurysm and patient-specific devices. Development of existing intrasaccular as well as new intrasaccular devices will be the hot topic of the future endovascular research. Hopefully, such newer devices and advances in technology will allow for safer and more robust aneurysm occlusion.



## 7 Conclusions

1. The endovascular treatment of wide-necked recurrent intracranial aneurysms with the Woven EndoBridge is feasible. The WEB provides adequate occlusion with a low rate of complications with respect to complexity of recurrent intracranial aneurysms. The occlusion appears to be stable after the WEB treatment.
2. The new generation Surpass Evolve flow diverter is promising device with high technical success and good safety profile. The short-term occlusion rate is promising.
3. The flow diverter treatment for acutely ruptured intracranial aneurysms yields high occlusion rate but is associated with a high overall complication rate.
4. The treatment of naïve wide-necked intracranial aneurysms with the Woven EndoBridge is not only safe, but also efficient comparing to conventional endovascular therapies. The high level of stability in aneurysm occlusion between 6- and 24-months follow-up is promising. Radiological outcomes may relate to the size and morphology of the aneurysm.

# Acknowledgements

This thesis was executed at the Department of Radiology at the Turku University Hospital between years 2019 and 2021. The thesis was financially supported by the Radiological Society of Finland, the Maire Taponen Foundation, and the Turku University Foundation.

I wish to express my sincere gratitude to my supervisors, professor Riitta (Ritu) Parkkola and adjunct professor Riitta Rautio for their continuous guidance, scientific as well as clinical education, and endless support. Even though Ritu, according to her opinion, has supervised enough thesis, as many as nine, she was eager as this would be her very first. And yes, we all know that you would like to revise the articles. As a mentor for me in the angioblab and supervisor of the thesis which was really her very first, Riitta deserves an Oscar for her both roles. Adjunct professor Antti Lindgren, you joined the team from bench, but did a lot better job than a starter. The way you read, criticize and revise manuscripts is tremendous. I promise you to organize a special karonkka after you are back to Finland. The first paper would not be possible without our collaborators from Edinburgh, I am very grateful to Dr. Jonny Downer and Dr. Alberto Nania. Hopefully our collaboration will continue in the future. I would like to thank you all our collaborators from Finnish university hospitals for their effort and contributions in Finnish Flow Diverter Study. I hope we will continue to pull out many papers together with our national and international collaborators.

I would like to thank warmly to the reviewers of the thesis appointed by the University of Turku, Faculty of Medicine, adjunct professor Miikka Korja and Niko Sillanpää for their valuable comments and advices to improve the academic value of the thesis. Furthermore, they coached me for this dissertation as reviewers.

I am sincerely grateful to professor Roberto Blanco for arranging me research leave whenever I needed, and encouraging me to start a career in the diagnostic radiology. I wish to express my gratitude to Dr. Matias Sinisalo for his support and motivation in and out of the hospital.

My parents and my sister. So much has gone on since I left home, not only this thesis, but also in the daily life. You have provided whatever I needed in any step of my life to achieve my goals.

Finally, and most importantly, Laura my wife. In addition to growing up our two amazing girls, you have supported me in any calls I took during the last years, changing the job, this thesis and much else in daily life. Olivia and Aili, our lovely daughters, thank you for teaching me what is the key for happiness and what is the most important thing in the life: FAMILY.

September 18<sup>th</sup>, 2022

*Kemal Alpay*

# References

- Adams, H., Ban, V. S., Leinonen, V., Aoun, S. G., Huttunen, J., Saavalainen, T., Lindgren, A., Frosen, J., Fraunberg, M., Koivisto, T., Hernesniemi, J., Welch, B. G., Jaaskelainen, J. E., & Huttunen, T. J. (2016). Risk of Shunting After Aneurysmal Subarachnoid Hemorrhage. *Stroke*, *47*(10), 2488–2496. <https://doi.org/10.1161/STROKEAHA.116.013739>
- Agid, R., Lee, S. K., Willinsky, R. A., Farb, R. I., & terBrugge, K. G. (2006). Acute subarachnoid hemorrhage: using 64-slice multidetector CT angiography to “triage” patients’ treatment. *Neuroradiology*, *48*(11), 787–794. <https://doi.org/10.1007/s00234-006-0129-5>
- Ahmed, S. U., Mocco, J., Zhang, X., Kelly, M., Doshi, A., Nael, K., & de Leacy, R. (2019). MRA versus DSA for the follow-up imaging of intracranial aneurysms treated using endovascular techniques: a meta-analysis. *Journal of NeuroInterventional Surgery*, *11*(10), 1009–1014. <https://doi.org/10.1136/neurintsurg-2019-014936>
- Akhunbay-Fudge, C. Y., Deniz, K., Tyagi, A. K., & Patankar, T. (2020). Endovascular treatment of wide-necked intracranial aneurysms using the novel Contour Neurovascular System: a single-center safety and feasibility study. *Journal of NeuroInterventional Surgery*, *12*(10), 987–992. <https://doi.org/10.1136/neurintsurg-2019-015628>
- Al-Khindi, T., Macdonald, R. L., & Schweizer, T. A. (2010). Cognitive and functional outcome after aneurysmal subarachnoid hemorrhage. *Stroke*, *41*(8), e519-36. <https://doi.org/10.1161/STROKEAHA.110.581975>
- Alotaibi, N. M., Elkarim, G. A., Samuel, N., Ayling, O. G. S., Guha, D., Fallah, A., Aldakkan, A., Jaja, B. N. R., de Oliveira Manoel, A. L., Ibrahim, G. M., & Macdonald, R. L. (2017). Effects of decompressive craniectomy on functional outcomes and death in poor-grade aneurysmal subarachnoid hemorrhage: a systematic review and meta-analysis. *Journal of Neurosurgery*, *127*(6), 1315–1325. <https://doi.org/10.3171/2016.9.JNS161383>
- Arthur, A. S., Molyneux, A., Coon, A. L., Saatci, I., Szikora, I., Baltacioglu, F., Sultan, A., Hoit, D., Delgado Almandoz, J. E., Elijovich, L., Cekirge, S., Byrne, J. v., & Fiorella, D. (2019). The safety and effectiveness of the Woven EndoBridge (WEB) system for the treatment of wide-necked bifurcation aneurysms: final 12-month results of the pivotal WEB Intracapsular Therapy (WEB-IT) Study. *Journal of NeuroInterventional Surgery*, *11*(9), 924–930. <https://doi.org/10.1136/neurintsurg-2019-014815>
- Asnafi, S., Rouchaud, A., Pierot, L., Brinjikji, W., Murad, M. H., & Kallmes, D. F. (2016). Efficacy and Safety of the Woven EndoBridge (WEB) Device for the Treatment of Intracranial Aneurysms: A Systematic Review and Meta-Analysis. *American Journal of Neuroradiology*, *37*(12), 2287–2292. <https://doi.org/10.3174/ajnr.A4900>
- Backes, D., Vergouwen, M. D. I., Velthuis, B. K., van der Schaaf, I. C., Bor, A. S. E., Algra, A., & Rinkel, G. J. E. (2014). Difference in aneurysm characteristics between ruptured and unruptured aneurysms in patients with multiple intracranial aneurysms. *Stroke*, *45*(5), 1299–1303. <https://doi.org/10.1161/STROKEAHA.113.004421>
- Barburoglu, M., & Arat, A. (2017). Flow diverters in the treatment of pediatric cerebrovascular diseases. *American Journal of Neuroradiology*, *38*(1), 113–118. <https://doi.org/10.3174/ajnr.A4959>

- Beckske, T., Brinjikji, W., Potts, M. B., Kallmes, D. F., Shapiro, M., Moran, C. J., Levy, E. I., McDougall, C. G., Szikora, I., Lanzino, G., Woo, H. H., Lopes, D. K., Siddiqui, A. H., Albuquerque, F. C., Fiorella, D. J., Saatci, I., Cekirge, S. H., Berez, A. L., Cher, D. J., ... Nelson, P. K. (2017). Long-Term Clinical and Angiographic Outcomes Following Pipeline Embolization Device Treatment of Complex Internal Carotid Artery Aneurysms: Five-Year Results of the Pipeline for Uncoilable or Failed Aneurysms Trial. *Neurosurgery*, *80*(1), 40–48. <https://doi.org/10.1093/neuros/nyw014>
- Beckske, T., Potts, M. B., Shapiro, M., Kallmes, D. F., Brinjikji, W., Saatci, I., McDougall, C. G., Szikora, I., Lanzino, G., Moran, C. J., Woo, H. H., Lopes, D. K., Berez, A. L., Cher, D. J., Siddiqui, A. H., Levy, E. I., Albuquerque, F. C., Fiorella, D. J., Berentei, Z., ... Nelson, P. K. (2017). Pipeline for uncoilable or failed aneurysms: 3-year follow-up results. *Journal of Neurosurgery*, *127*(1), 81–88. <https://doi.org/10.3171/2015.6.JNS15311>
- Bell, R. S., Ecker, R. D., Severson, M. A., Wanebo, J. E., Crandall, B., & Armonda, R. A. (2010). The evolution of the treatment of traumatic cerebrovascular injury during wartime. *Neurosurgical Focus*, *28*(5), E5. <https://doi.org/10.3171/2010.2.FOCUS1025>
- Bell, R. S., Vo, A. H., Roberts, R., Wanebo, J., & Armonda, R. A. (2010). Wartime traumatic aneurysms: acute presentation, diagnosis, and multimodal treatment of 64 craniocervical arterial injuries. *Neurosurgery*, *66*(1), 66–79; discussion 79. <https://doi.org/10.1227/01.NEU.0000361285.50218.A8>
- Bender, M. T., Vo, C. D., Jiang, B., Campos, J. K., Zarrin, D. A., Xu, R., Westbroek, E. M., Caplan, J. M., Huang, J., Tamargo, R. J., Lin, L.-M., Colby, G. P., & Coon, A. L. (2018). Pipeline Embolization for Salvage Treatment of Previously Stented Residual and Recurrent Cerebral Aneurysms. *Interventional Neurology*, *7*(6), 359–369. <https://doi.org/10.1159/000489018>
- Bendok, B. R., Abi-Aad, K. R., Ward, J. D., Kniss, J. F., Kwasny, M. J., Rahme, R. J., Aoun, S. G., el Ahmadi, T. Y., el Tecle, N. E., Zammar, S. G., Aoun, R. J. N., Patra, D. P., Ansari, S. A., Raymond, J., Woo, H. H., Fiorella, D., Dabus, G., Milot, G., Delgado Almandoz, J. E., ... Hartman, J. (2020). The Hydrogel Endovascular Aneurysm Treatment Trial (HEAT): A Randomized Controlled Trial of the Second-Generation Hydrogel Coil. *Neurosurgery*, *86*(5), 615–624. <https://doi.org/10.1093/neuros/nyaa006>
- Benke, T., Köylü, B., Delazer, M., Trinka, E., & Kemmler, G. (2005). Cholinergic treatment of amnesia following basal forebrain lesion due to aneurysm rupture--an open-label pilot study. *European Journal of Neurology*, *12*(10), 791–796. <https://doi.org/10.1111/j.1468-1331.2005.01063.x>
- Bergqvist, D. (2008). Historical aspects on aneurysmal disease. In *Scandinavian Journal of Surgery* (Vol. 97).
- Bhatia, K. D., Kortman, H., Orru, E., Klostranec, J. M., Pereira, V. M., & Krings, T. (2019). Periprocedural complications of second-generation flow diverter treatment using Pipeline Flex for unruptured intracranial aneurysms: a systematic review and meta-analysis. *Journal of NeuroInterventional Surgery*, *11*(8), 817–824. <https://doi.org/10.1136/neurintsurg-2019-014937>
- Bhagal, P., Loh, Y., Brouwer, P., Andersson, T., & Söderman, M. (2017). Treatment of cerebral vasospasm with self-expandable retrievable stents: proof of concept. *Journal of NeuroInterventional Surgery*, *9*(1), 52–59. <https://doi.org/10.1136/neurintsurg-2016-012546>
- Bhagal, P., Lylyk, I., Chudyk, J., Perez, N., Bleise, C., & Lylyk, P. (2021). The Contour—Early Human Experience of a Novel Aneurysm Occlusion Device. *Clinical Neuroradiology*, *31*(1), 147–154. <https://doi.org/10.1007/s00062-020-00876-4>
- Bhagal, P., Udani, S., Cognard, C., Piotin, M., Brouwer, P., Sourour, N.-A., Andersson, T., Makalanda, L., Wong, K., Fiorella, D., Arthur, A. S., Yeo, L. L., Soderman, M., Henkes, H., & Pierot, L. (2019). Endosaccular flow disruption: where are we now? *Journal of NeuroInterventional Surgery*, *11*(10), 1024–1025. <https://doi.org/10.1136/neurintsurg-2018-014623>
- Black, P. McL. (1986). Hydrocephalus and Vasospasm after Subarachnoid Hemorrhage from Ruptured Intracranial Aneurysms. *Neurosurgery*, *18*(1), 12–16. <https://doi.org/10.1227/00006123-198601000-00003>

- Bohnstedt, B. N., Nguyen, H. S., Kulwin, C. G., Shoja, M. M., Helbig, G. M., Leipzig, T. J., Payner, T. D., & Cohen-Gadol, A. A. (2013). Outcomes for Clip Ligation and Hematoma Evacuation Associated with 102 Patients with Ruptured Middle Cerebral Artery Aneurysms. *World Neurosurgery*, *80*(3–4), 335–341. <https://doi.org/10.1016/j.wneu.2012.03.008>
- Boogaarts, H. D., van Amerongen, M. J., de Vries, J., Westert, G. P., Verbeek, A. L. M., Grotenhuis, J. A., & Bartels, R. H. M. A. (2014). Caseload as a factor for outcome in aneurysmal subarachnoid hemorrhage: a systematic review and meta-analysis. *Journal of Neurosurgery*, *120*(3), 605–611. <https://doi.org/10.3171/2013.9.JNS13640>
- Brinjikji, W., Murad, M. H., Lanzino, G., Cloft, H. J., & Kallmes, D. F. (2013). Endovascular Treatment of Intracranial Aneurysms With Flow Diverters. *Stroke*, *44*(2), 442–447. <https://doi.org/10.1161/STROKEAHA.112.678151>
- Brinjikji, W., Rabinstein, A. A., Nasr, D. M., Lanzino, G., Kallmes, D. F., & Cloft, H. J. (2011). Better Outcomes with Treatment by Coiling Relative to Clipping of Unruptured Intracranial Aneurysms in the United States, 2001–2008. *American Journal of Neuroradiology*, *32*(6), 1071–1075. <https://doi.org/10.3174/ajnr.A2453>
- Britz, G. W., Salem, L., Newell, D. W., Eskridge, J., & Flum, D. R. (2004). Impact of Surgical Clipping on Survival in Unruptured and Ruptured Cerebral Aneurysms. *Stroke*, *35*(6), 1399–1403. <https://doi.org/10.1161/01.STR.0000128706.41021.01>
- Broderick, J. P., Brown, R. D., Sauerbeck, L., Hornung, R., Huston, J., Woo, D., Anderson, C., Rouleau, G., Kleindorfer, D., Flaherty, M. L., Meissner, I., Foroud, T., Moomaw, E. C. J., Connolly, E. S., & FIA Study Investigators. (2009). Greater rupture risk for familial as compared to sporadic unruptured intracranial aneurysms. *Stroke*, *40*(6), 1952–1957. <https://doi.org/10.1161/STROKEAHA.108.542571>
- Brown, R. D., Huston, J., Hornung, R., Foroud, T., Kallmes, D. F., Kleindorfer, D., Meissner, I., Woo, D., Sauerbeck, L., & Broderick, J. (2008). Screening for brain aneurysm in the Familial Intracranial Aneurysm study: Frequency and predictors of lesion detection. *Journal of Neurosurgery*, *108*(6), 1132–1138. <https://doi.org/10.3171/JNS/2008/108/6/1132>
- Bsat, S., Bsat, A., Tamim, H., Chanbour, H., Alomari, S. O., Houshiemy, M. N. el, Moussalem, C., & Omeis, I. (2020). Safety of stent-assisted coiling for the treatment of wide-necked ruptured aneurysm: A systematic literature review and meta-analysis of prevalence. *Interventional Neuroradiology: Journal of Peritherapeutic Neuroradiology, Surgical Procedures and Related Neurosciences*, *26*(5), 547–556. <https://doi.org/10.1177/1591019920945059>
- Butzkueven, H., Evans, A. H., Pitman, A., Leopold, C., Jolley, D. J., Kaye, A. H., Kilpatrick, C. J., & Davis, S. M. (2000). Onset seizures independently predict poor outcome after subarachnoid hemorrhage. *Neurology*, *55*(9), 1315–1320. <https://doi.org/10.1212/WNL.55.9.1315>
- Cagnazzo, F., Ahmed, R., Zannoni, R., Dargazanli, C., Lefevre, P.-H., Gascou, G., Derraz, I., Riquelme, C., Bonafe, A., & Costalat, V. (2019). Predicting Factors of Angiographic Aneurysm Occlusion after Treatment with the Woven EndoBridge Device: A Single-Center Experience with Midterm Follow-Up. *AJNR. American Journal of Neuroradiology*, *40*(10), 1773–1778. <https://doi.org/10.3174/ajnr.A6221>
- Cagnazzo, F., di Carlo, D. T., Cappucci, M., Lefevre, P.-H., Costalat, V., & Perrini, P. (2018). Acutely Ruptured Intracranial Aneurysms Treated with Flow-Diverter Stents: A Systematic Review and Meta-Analysis. *AJNR. American Journal of Neuroradiology*, *39*(9), 1669–1675. <https://doi.org/10.3174/ajnr.A5730>
- Cagnazzo, F., Mantilla, D., Lefevre, P.-H., Dargazanli, C., Gascou, G., & Costalat, V. (2017). Treatment of Middle Cerebral Artery Aneurysms with Flow-Diverter Stents: A Systematic Review and Meta-Analysis. *American Journal of Neuroradiology*, *38*(12), 2289–2294. <https://doi.org/10.3174/ajnr.A5388>
- Campi, A., Ramzi, N., Molyneux, A. J., Summers, P. E., Kerr, R. S. C., Sneade, M., Yarnold, J. A., Rischmiller, J., & Byrne, J. v. (2007a). Retreatment of Ruptured Cerebral Aneurysms in Patients

- Randomized by Coiling or Clipping in the International Subarachnoid Aneurysm Trial (ISAT). *Stroke*, *38*(5), 1538–1544. <https://doi.org/10.1161/STROKEAHA.106.466987>
- Campi, A., Ramzi, N., Molyneux, A. J., Summers, P. E., Kerr, R. S. C., Sneade, M., Yarnold, J. A., Rischmiller, J., & Byrne, J. v. (2007b). Retreatment of Ruptured Cerebral Aneurysms in Patients Randomized by Coiling or Clipping in the International Subarachnoid Aneurysm Trial (ISAT). *Stroke*, *38*(5), 1538–1544. <https://doi.org/10.1161/STROKEAHA.106.466987>
- Caroff, J., Cortese, J., Girot, J.-B., Mihalea, C., Aguiar, G., Vergara Martinez, J., Ikka, L., Chalumeau, V., Rehem, M., Gallas, S., Ozanne, A., Moret, J., & Spelle, L. (2021). Woven EndoBridge device shape modification can be mitigated with an appropriate oversizing strategy: a VasoCT based study. *Journal of NeuroInterventional Surgery*, neurintsurg-2020-017232. <https://doi.org/10.1136/neurintsurg-2020-017232>
- Caroff, J., Mihalea, C., Klisch, J., Strasilla, C., Berlis, A., Patankar, T., Weber, W., Behme, D., Jacobsen, E. A., Liebig, T., Prothmann, S., Cognard, C., Finkenzeller, T., Moret, J., & Spelle, L. (2015). Single-Layer WEBS: Intracardiac Flow Disrupters for Aneurysm Treatment—Feasibility Results from a European Study. *American Journal of Neuroradiology*, *36*(10), 1942–1946. <https://doi.org/10.3174/ajnr.A4369>
- Caroff, J., Neki, H., Mihalea, C., D'Argento, F., Abdel Khalek, H., Ikka, L., Moret, J., & Spelle, L. (2016). Flow-Diverter Stents for the Treatment of Saccular Middle Cerebral Artery Bifurcation Aneurysms. *American Journal of Neuroradiology*, *37*(2), 279–284. <https://doi.org/10.3174/ajnr.A4540>
- Chalouhi, N., Chitale, R., Starke, R. M., Jabbour, P., Tjoumakaris, S., Dumont, A. S., Rosenwasser, R. H., & Gonzalez, L. F. (2014). Treatment of recurrent intracranial aneurysms with the Pipeline Embolization Device. *Journal of NeuroInterventional Surgery*, *6*(1), 19–23. <https://doi.org/10.1136/neurintsurg-2012-010612>
- Chalouhi, N., Jabbour, P., Singhal, S., Drueding, R., Starke, R. M., Dalyai, R. T., Tjoumakaris, S., Gonzalez, L. F., Dumont, A. S., Rosenwasser, R., & Randazzo, C. G. (2013). Stent-Assisted Coiling of Intracranial Aneurysms. *Stroke*, *44*(5), 1348–1353. <https://doi.org/10.1161/STROKEAHA.111.000641>
- Chancellor, B., Raz, E., Shapiro, M., Tanweer, O., Nossek, E., Riina, H. A., & Nelson, P. K. (2020a). Flow Diversion for Intracranial Aneurysm Treatment: Trials Involving Flow Diverters and Long-Term Outcomes. *Neurosurgery*, *86*(Suppl 1), S36–S45. <https://doi.org/10.1093/neuros/nyz345>
- Chen, Y.-C., Sun, Z.-K., Li, M.-H., Li, Y.-D., Wang, W., Tan, H.-Q., Gu, B.-X., & Chen, S.-W. (2012). The clinical value of MRA at 3.0 T for the diagnosis and therapeutic planning of patients with subarachnoid haemorrhage. *European Radiology*, *22*(7), 1404–1412. <https://doi.org/10.1007/s00330-012-2390-9>
- Claassen, J., Mayer, S. A., Kowalski, R. G., Emerson, R. G., & Hirsch, L. J. (2004). Detection of electrographic seizures with continuous EEG monitoring in critically ill patients. *Neurology*, *62*(10), 1743–1748. <https://doi.org/10.1212/01.WNL.0000125184.88797.62>
- Clarke, G., Mendelow, A. D., & Mitchell, P. (2005). Predicting the risk of rupture of intracranial aneurysms based on anatomical location. In *Acta neurochirurgica* (Vol. 147, Issue 3). <https://doi.org/10.1007/s00701-004-0473-3>
- Cognard, C., & Januel, A. C. (2015). Remnants and recurrences after the use of the WEB intracardiac device in large-neck bifurcation aneurysms. *Neurosurgery*, *76*(5), 522-30;discussion 530. <https://doi.org/10.1227/NEU.0000000000000669>
- Cohen, J. E., Gomori, J. M., Moscovici, S., Kaye, A. H., Shoshan, Y., Spektor, S., & Leker, R. R. (2021). Flow-diverter stents in the early management of acutely ruptured brain aneurysms: effective rebleeding protection with low thromboembolic complications. *Journal of Neurosurgery*, 1–8. <https://doi.org/10.3171/2020.10.JNS201642>
- Connolly, E. S., Rabinstein, A. A., Carhuapoma, J. R., Derdeyn, C. P., Dion, J., Higashida, R. T., Hoh, B. L., Kirkness, C. J., Naidech, A. M., Ogilvy, C. S., Patel, A. B., Thompson, B. G., & Vespa, P.

- (2012). Guidelines for the Management of Aneurysmal Subarachnoid Hemorrhage. *Stroke*, 43(6), 1711–1737. <https://doi.org/10.1161/STR.0b013e3182587839>
- Consoli, A., Vignoli, C., Renieri, L., Rosi, A., Chiarotti, I., Nappini, S., Limbucci, N., & Mangiafico, S. (2016). Assisted coiling of saccular wide-necked unruptured intracranial aneurysms: Stent versus balloon. *Journal of NeuroInterventional Surgery*. <https://doi.org/10.1136/neurintsurg-2014-011466>
- Crobeddu, E., Lanzino, G., Kallmes, D. F., & Cloft, H. J. (2013). Review of 2 Decades of Aneurysm-Recurrence Literature, Part 2: Managing Recurrence after Endovascular Coiling. *American Journal of Neuroradiology*, 34(3), 481–485. <https://doi.org/10.3174/ajnr.A2958>
- Dandy, EW. *Intracranial aneurysm of the internal carotid artery cured by operation. Ann Surg 1938; 107: 654–659.* (n.d.).
- Daou, B., Starke, R. M., Chalouhi, N., Tjoumakaris, S., Hasan, D., Khoury, J., Rosenwasser, R. H., & Jabbour, P. (2016). Pipeline Embolization Device in the Treatment of Recurrent Previously Stented Cerebral Aneurysms. *AJNR. American Journal of Neuroradiology*, 37(5), 849–855. <https://doi.org/10.3174/ajnr.A4613>
- Darkwah Oppong, M., Skowronek, V., Pierscianek, D., Gembruch, O., Herten, A., Saban, D. V., Dammann, P., Forsting, M., Sure, U., & Jabbarli, R. (2018). Aneurysmal intracerebral hematoma: Risk factors and surgical treatment decisions. *Clinical Neurology and Neurosurgery*, 173, 1–7. <https://doi.org/10.1016/j.clineuro.2018.07.014>
- Davies, J. M., & Lawton, M. T. (2014). Advances in Open Microsurgery for Cerebral Aneurysms. *Neurosurgery*, 74(suppl\_1), S7–S16. <https://doi.org/10.1227/NEU.0000000000000193>
- Dawkins, A. A., Evans, A. L., Wattam, J., Romanowski, C. A. J., Connolly, D. J. A., Hodgson, T. J., & Coley, S. C. (2007). Complications of cerebral angiography: a prospective analysis of 2,924 consecutive procedures. *Neuroradiology*, 49(9), 753–759. <https://doi.org/10.1007/s00234-007-0252-y>
- de Rooij, N. K., Linn, F. H. H., van der Plas, J. A., Algra, A., & Rinkel, G. J. E. (2007). Incidence of subarachnoid haemorrhage: A systematic review with emphasis on region, age, gender and time trends. *Journal of Neurology, Neurosurgery and Psychiatry*, 78(12), 1365–1372. <https://doi.org/10.1136/jnnp.2007.117655>
- Debrun, G. M., Aletich, V. A., Kehrli, P., Misra, M., Ausman, J. I., & Charbel, F. (1998). Selection of cerebral aneurysms for treatment using Guglielmi detachable coils: the preliminary University of Illinois at Chicago experience. *Neurosurgery*, 43(6), 1281–1295; discussion 1296-7. <https://doi.org/10.1097/00006123-199812000-00011>
- Delgado Almandoz, J. E., Jagadeesan, B. D., Refai, D., Moran, C. J., Cross, D. T., Chicoine, M. R., Rich, K. M., Diringer, M. N., Dacey, R. G., Derdeyn, C. P., & Zipfel, G. J. (2012). Diagnostic Yield of Repeat Catheter Angiography in Patients With Catheter and Computed Tomography Angiography Negative Subarachnoid Hemorrhage. *Neurosurgery*, 70(5), 1135–1142. <https://doi.org/10.1227/NEU.0b013e318242575e>
- Dhandapani, S., Singh, A., Singla, N., Praneeth, K., Aggarwal, A., Sodhi, H. B., Pal, S. S., Goudihalli, S., Salunke, P., Mohindra, S., Kumar, A., Gupta, V., Chhabra, R., Mukherjee, K. K., Tewari, M. K., Khandelwal, N., Mathuriya, S. N., Khosla, V. K., & Gupta, S. K. (2018). Has Outcome of Subarachnoid Hemorrhage Changed With Improvements in Neurosurgical Services? *Stroke*, 49(12), 2890–2895. <https://doi.org/10.1161/STROKEAHA.118.022865>
- Ding, A., Braschkat, A., Guber, A., & Cattaneo, G. (2021). New Concept of Patient-specific Flow Diversion Treatment of Intracranial Aneurysms. *Clinical Neuroradiology*, 31(3), 671–679. <https://doi.org/10.1007/s00062-020-00930-1>
- Dion, J. E., Gates, P. C., Fox, A. J., Barnett, H. J., & Blom, R. J. (1987). Clinical events following neuroangiography: a prospective study. *Stroke*, 18(6), 997–1004. <https://doi.org/10.1161/01.STR.18.6.997>



- Dmytriw, A. A., Phan, K., Moore, J. M., Pereira, V. M., Krings, T., & Thomas, A. J. (2019). On Flow Diversion: The Changing Landscape of Intracerebral Aneurysm Management. *AJNR. American Journal of Neuroradiology*, *40*(4), 591–600. <https://doi.org/10.3174/ajnr.A6006>
- Dornbos, D., Karras, C. L., Wenger, N., Priddy, B., Youssef, P., Nimjee, S. M., & Powers, C. J. (2017). Pipeline embolization device for recurrence of previously treated aneurysms. *Neurosurgical Focus*, *42*(6), E8. <https://doi.org/10.3171/2017.3.FOCUS1744>
- Ducruet, A. F., Hickman, Z. L., Zacharia, B. E., Narula, R., Grobelny, B. T., Gorski, J., & Connolly, E. S. (2010). Intracranial infectious aneurysms: A comprehensive review. *Neurosurgical Review*, *33*(1), 37–46. <https://doi.org/10.1007/s10143-009-0233-1>
- Duits, F. H., Martinez-Lage, P., Paquet, C., Engelborghs, S., Lleó, A., Hausner, L., Molinuevo, J. L., Stomrud, E., Farotti, L., Ramakers, I. H. G. B., Tsolaki, M., Skarsgård, C., Åstrand, R., Wallin, A., Vyhnaek, M., Holmber-Clausen, M., Forlenza, O. v., Ghezzi, L., Ingelsson, M., ... Blennow, K. (2016). Performance and complications of lumbar puncture in memory clinics: Results of the multicenter lumbar puncture feasibility study. *Alzheimer's & Dementia*, *12*(2), 154–163. <https://doi.org/10.1016/j.jalz.2015.08.003>
- Edjlali, M., Guédon, A., ben Hassen, W., Boulouis, G., Benzakoun, J., Rodriguez-Régent, C., Trystram, D., Nataf, F., Meder, J.-F., Turski, P., Oppenheim, C., & Naggara, O. (2018). Circumferential Thick Enhancement at Vessel Wall MRI Has High Specificity for Intracranial Aneurysm Instability. *Radiology*, *289*(1), 181–187. <https://doi.org/10.1148/radiol.2018172879>
- Edlow, J. A., & Wyer, P. C. (2000). How good is a negative cranial computed tomographic scan result in excluding subarachnoid hemorrhage? *Annals of Emergency Medicine*, *36*(5), 507–516. <https://doi.org/10.1067/mem.2000.109449>
- Eskridge, J. M., Song, J. K., & \_\_. (1998). Endovascular embolization of 150 basilar tip aneurysms with Guglielmi detachable coils: results of the Food and Drug Administration multicenter clinical trial. *Journal of Neurosurgery*, *89*(1), 81–86. <https://doi.org/10.3171/jns.1998.89.1.0081>
- Essibayi, M. A., Lanzino, G., & Brinjikji, W. (2021). Safety and Efficacy of the Woven EndoBridge Device for Treatment of Ruptured Intracranial Aneurysms: A Systematic Review and Meta-analysis. *American Journal of Neuroradiology*, *42*(9), 1627–1632. <https://doi.org/10.3174/ajnr.A7174>
- Etminan, N., Brown, R. D., Beseoglu, K., Juvela, S., Raymond, J., Morita, A., Torner, J. C., Derdeyn, C. P., Raabe, A., Mocco, J., Korja, M., Abdulazim, A., Amin-Hanjani, S., Al-Shahi Salman, R., Barrow, D. L., Bederson, J., Bonafe, A., Dumont, A. S., Fiorella, D. J., ... Macdonald, R. L. (2015). The unruptured intracranial aneurysm treatment score. *Neurology*, *85*(10), 881–889. <https://doi.org/10.1212/WNL.0000000000001891>
- Etminan, N., Chang, H.-S., Hackenberg, K., de Rooij, N. K., Vergouwen, M. D. I., Rinkel, G. J. E., & Algra, A. (2019). Worldwide Incidence of Aneurysmal Subarachnoid Hemorrhage According to Region, Time Period, Blood Pressure, and Smoking Prevalence in the Population. *JAMA Neurology*, *76*(5), 588. <https://doi.org/10.1001/jamaneurol.2019.0006>
- Etminan, N., Dreier, R., Buchholz, B. A., Beseoglu, K., Bruckner, P., Matzenauer, C., Torner, J. C., Brown, R. D., Steiger, H.-J., Hänggi, D., & Macdonald, R. L. (2014). Age of collagen in intracranial saccular aneurysms. *Stroke*, *45*(6), 1757–1763. <https://doi.org/10.1161/STROKEAHA.114.005461>
- Etminan, N., & Rinkel, G. J. (2016). Unruptured intracranial aneurysms: Development, rupture and preventive management. In *Nature Reviews Neurology* (Vol. 12, Issue 12, pp. 699–713). Nature Publishing Group. <https://doi.org/10.1038/nrneurol.2016.150>
- Falk Delgado, A., Andersson, T., & Falk Delgado, A. (2017). Clinical outcome after surgical clipping or endovascular coiling for cerebral aneurysms: a pragmatic meta-analysis of randomized and non-randomized trials with short- and long-term follow-up. *Journal of NeuroInterventional Surgery*, *9*(3), 264–277. <https://doi.org/10.1136/neurintsurg-2016-012292>

- Feigin, V. L., Lawes, C. M., Bennett, D. A., Barker-Collo, S. L., & Parag, V. (2009). Worldwide stroke incidence and early case fatality reported in 56 population-based studies: a systematic review. *The Lancet Neurology*, 8(4), 355–369. [https://doi.org/10.1016/S1474-4422\(09\)70025-0](https://doi.org/10.1016/S1474-4422(09)70025-0)
- Feng, M.-T., Wen, W.-L., Feng, Z.-Z., Fang, Y.-B., Liu, J.-M., & Huang, Q.-H. (2016). Endovascular Embolization of Intracranial Aneurysms: To Use Stent(s) or Not? Systematic Review and Meta-analysis. *World Neurosurgery*, 93, 271–278. <https://doi.org/10.1016/j.wneu.2016.06.014>
- Fernandez Zubillaga, A., Guglielmi, G., Viñuela, F., & Duckwiler, G. R. (1994). Endovascular occlusion of intracranial aneurysms with electrically detachable coils: correlation of aneurysm neck size and treatment results. *AJNR. American Journal of Neuroradiology*, 15(5), 815–820.
- Ferns, S. P., Sprengers, M. E. S., van Rooij, W. J., Rinkel, G. J. E., van Rijn, J. C., Bipat, S., Sluzewski, M., & Majoie, C. B. L. M. (2009a). Coiling of intracranial aneurysms: A systematic review on initial occlusion and reopening and retreatment rates. *Stroke*. <https://doi.org/10.1161/STROKEAHA.109.553099>
- Ferns, S. P., Sprengers, M. E. S., van Rooij, W. J., Rinkel, G. J. E., van Rijn, J. C., Bipat, S., Sluzewski, M., & Majoie, C. B. L. M. (2009b). Coiling of Intracranial Aneurysms. *Stroke*, 40(8). <https://doi.org/10.1161/STROKEAHA.109.553099>
- Ferns, S. P., Sprengers, M. E. S., van Rooij, W. J., van Zwam, W. H., de Kort, G. A. P., Velthuis, B. K., Schaafsma, J. D., van den Berg, R., Sluzewski, M., Brouwer, P. A., Rinkel, G. J. E., & Majoie, C. B. L. M. (2011). Late Reopening of Adequately Coiled Intracranial Aneurysms. *Stroke*, 42(5), 1331–1337. <https://doi.org/10.1161/STROKEAHA.110.605790>
- Fiorella, D., Molyneux, A., Coon, A., Szikora, I., Saatci, I., Baltacioglu, F., Sultan, A., & Arthur, A. (2017). Demographic, procedural and 30-day safety results from the WEB Intra-saccular Therapy Study (WEB-IT). *Journal of NeuroInterventional Surgery*, 9(12), 1191–1196. <https://doi.org/10.1136/neurintsurg-2016-012841>
- Foreman, B. (2016). The Pathophysiology of Delayed Cerebral Ischemia. *Journal of Clinical Neurophysiology*, 33(3), 174–182. <https://doi.org/10.1097/WNP.0000000000000273>
- Frontera, J. A., Fernandez, A., Claassen, J., Schmidt, M., Schumacher, H. C., Wartenberg, K., Temes, R., Parra, A., Ostapkovich, N. D., & Mayer, S. A. (2006). Hyperglycemia After SAH. *Stroke*, 37(1), 199–203. <https://doi.org/10.1161/01.STR.0000194960.73883.0f>
- Frösen, J., Tulamo, R., Paetau, A., Laaksamo, E., Korja, M., Laakso, A., Niemelä, M., & Hernesniemi, J. (2012). Saccular intracranial aneurysm: Pathology and mechanisms. In *Acta Neuropathologica* (Vol. 123, Issue 6, pp. 773–786). <https://doi.org/10.1007/s00401-011-0939-3>
- Garg, K., Singh, P. K., Sharma, B. S., Chandra, P. S., Suri, A., Singh, M., Kumar, R., Kale, S. S., Mishra, N. K., Gaikwad, S. K., & Mahapatra, A. K. (2014). Pediatric intracranial aneurysms - Our experience and review of literature. *Child's Nervous System*, 30(5), 873–883. <https://doi.org/10.1007/s00381-013-2336-9>
- Gathier, C. S., van den Bergh, W. M., van der Jagt, M., Verweij, B. H., Dankbaar, J. W., Müller, M. C., Oldenbeuving, A. W., Rinkel, G. J. E., Slooter, A. J. C., Algra, A., Kesecioglu, J., van der Schaaf, I. C., Dammers, R., Dippel, D. W. J., Dirven, C. M. F., van Kooten, F., van der Lugt, A., Coert, B. A., Horn, J., ... Sluzewski, M. (2018). Induced Hypertension for Delayed Cerebral Ischemia After Aneurysmal Subarachnoid Hemorrhage. *Stroke*, 49(1), 76–83. <https://doi.org/10.1161/STROKEAHA.117.017956>
- Gawlitza, M., Soize, S., Januel, A. C., Mihalea, C., Metaxas, G. E., Cognard, C., & Pierot, L. (2018a). Treatment of recurrent aneurysms using the Woven EndoBridge (WEB): Anatomical and clinical results. *Journal of NeuroInterventional Surgery*. <https://doi.org/10.1136/neurintsurg-2017-013287>
- Görlitz, P., Luecking, H., Hoelter, P., Knossalla, F., & Doerfler, A. (2020). What is the hemodynamic effect of the Woven EndoBridge? An in vivo quantification using time-density curve analysis. *Neuroradiology*, 62(8), 1043–1050. <https://doi.org/10.1007/s00234-020-02390-3>
- Goyal, N., Hoit, D., DiNitto, J., Eljovich, L., Fiorella, D., Pierot, L., Lamin, S., Spelle, L., Saatci, I., Cekirge, S., & Arthur, A. S. (2020). How to WEB: a practical review of methodology for the use

- of the Woven EndoBridge. *Journal of NeuroInterventional Surgery*, 12(5), 512–520. <https://doi.org/10.1136/neurintsurg-2019-015506>
- Greving, J. P., Wermer, M. J. H., Brown, R. D., Morita, A., Juvela, S., Yonekura, M., Ishibashi, T., Torner, J. C., Nakayama, T., Rinkel, G. J. E., & Algra, A. (2014a). Development of the PHASES score for prediction of risk of rupture of intracranial aneurysms: a pooled analysis of six prospective cohort studies. *The Lancet Neurology*, 13(1), 59–66. [https://doi.org/10.1016/S1474-4422\(13\)70263-1](https://doi.org/10.1016/S1474-4422(13)70263-1)
- Greving, J. P., Wermer, M. J. H., Brown, R. D., Morita, A., Juvela, S., Yonekura, M., Ishibashi, T., Torner, J. C., Nakayama, T., Rinkel, G. J. E., & Algra, A. (2014b). Development of the PHASES score for prediction of risk of rupture of intracranial aneurysms: A pooled analysis of six prospective cohort studies. *The Lancet Neurology*, 13(1), 59–66. [https://doi.org/10.1016/S1474-4422\(13\)70263-1](https://doi.org/10.1016/S1474-4422(13)70263-1)
- Gross, B. A., Smith, E. R., Scott, R. M., & Orbach, D. B. (2015). Intracranial aneurysms in the youngest patients: Characteristics and treatment challenges. *Pediatric Neurosurgery*, 50(1), 18–25. <https://doi.org/10.1159/000370161>
- Guglielmi, G., Viñuela, F., Dion, J., & Duckwiler, G. (1991). Electrothrombosis of saccular aneurysms via endovascular approach. *Journal of Neurosurgery*, 75(1), 8–14. <https://doi.org/10.3171/jns.1991.75.1.0008>
- Güresir, E., Beck, J., Vatter, H., Setzer, M., Gerlach, R., Seifert, V., & Raabe, A. (2008). SUBARACHNOID HEMORRHAGE AND INTRACEREBRAL HEMATOMA. *Neurosurgery*, 63(6), 1088–1094. <https://doi.org/10.1227/01.NEU.0000335170.76722.B9>
- Hadjivassiliou, M., Tooth, C. L., Romanowski, C. A., Byrne, J., Battersby, R. D., Oxbury, S., Crewswell, C. S., Burkitt, E., Stokes, N. A., Paul, C., Mayes, A. R., & Sagar, H. J. (2001). Aneurysmal SAH: cognitive outcome and structural damage after clipping or coiling. *Neurology*, 56(12), 1672–1677. <https://doi.org/10.1212/wnl.56.12.1672>
- Hanel, R. A., Kallmes, D. F., Lopes, D. K., Nelson, P. K., Siddiqui, A., Jabbour, P., Pereira, V. M., Szikora István, I., Zaidat, O. O., Bettgowda, C., Colby, G. P., Mokin, M., Schirmer, C., Hellinger, F. R., Given Li, C., Krings, T., Taussky, P., Toth, G., Fraser, J. F., ... Puri, A. S. (2020). Prospective study on embolization of intracranial aneurysms with the pipeline device: the PREMIER study 1 year results. *Journal of Neurointerventional Surgery*, 12(1), 62–66. <https://doi.org/10.1136/neurintsurg-2019-015091>
- Hara, M., & Yamamoto, I. (2000). Introduction to symposium: intracranial dissecting aneurysms. *Neuropathology: Official Journal of the Japanese Society of Neuropathology*, 20(1), 83–84. <https://doi.org/10.1046/j.1440-1789.2000.00273.x>
- Hart, Y., Sneade, M., Birks, J., Rischmiller, J., Kerr, R., & Molyneux, A. (2011). Epilepsy after subarachnoid hemorrhage: the frequency of seizures after clip occlusion or coil embolization of a ruptured cerebral aneurysm. *Journal of Neurosurgery*, 115(6), 1159–1168. <https://doi.org/10.3171/2011.6.JNS101836>
- Heiskanen, O., Poranen, A., Kuurne, T., Valtonen, S., & Kaste, M. (1988). Acute surgery for intracerebral haematomas caused by rupture of an intracranial arterial aneurysm. *Acta Neurochirurgica*, 90(3–4), 81–83. <https://doi.org/10.1007/BF01560559>
- Henkes, H., Fischer, S., Liebig, T., Weber, W., Reinartz, J., Miloslavski, E., & Kühne, D. (2006). Repeated endovascular coil occlusion in 350 of 2759 intracranial aneurysms: Safety and effectiveness aspects. *Neurosurgery*. <https://doi.org/10.1227/01.NEU.0000194831.54183.3F>
- Henkes, H., & Weber, W. (2015). The Past, Present and Future of Endovascular Aneurysm Treatment. *Clinical Neuroradiology*, 25(S2), 317–324. <https://doi.org/10.1007/s00062-015-0403-1>
- Hitchcock, E., & Gibson, W. T. (2017). A Review of the Genetics of Intracranial Berry Aneurysms and Implications for Genetic Counseling. *Journal of Genetic Counseling*, 26(1), 21–31. <https://doi.org/10.1007/s10897-016-0029-8>
- Hoh, B. L., Nathoo, S., Chi, Y.-Y., Mocco, J., & Barker, F. G. (2011). Incidence of Seizures or Epilepsy After Clipping or Coiling of Ruptured and Unruptured Cerebral Aneurysms in the Nationwide

- Inpatient Sample Database: 2002-2007. *Neurosurgery*, 69(3), 644–650. <https://doi.org/10.1227/NEU.0b013e31821bc46d>
- Horstman, P., Linn, F. H. H., Voorbij, H. A. M., & Rinkel, G. J. E. (2012). Chance of aneurysm in patients suspected of SAH who have a ‘negative’ CT scan but a ‘positive’ lumbar puncture. *Journal of Neurology*, 259(4), 649–652. <https://doi.org/10.1007/s00415-011-6228-1>
- Inagawa, T. (2010). Risk factors for the formation and rupture of intracranial saccular aneurysms in Shimane, Japan. *World Neurosurgery*, 73(3), 155–164. <https://doi.org/10.1016/j.surneu.2009.03.007>
- Inamasu, J., Sadato, A., Oheda, M., Hayakawa, M., Nakae, S., Ohmi, T., Adachi, K., Nakahara, I., & Hirose, Y. (2016). Improvement in patient outcomes following endovascular treatment of WFNS grade V subarachnoid haemorrhage from 2000 to 2014. *Journal of Clinical Neuroscience*, 27, 114–118. <https://doi.org/10.1016/j.jocn.2015.08.043>
- Ishikawa, T., Nakamura, N., Houkin, K., & Nomura, M. (1997). Pathological consideration of a “blister-like” aneurysm at the superior wall of the internal carotid artery: case report. *Neurosurgery*, 40(2), 403–405; discussion 405-6. <https://doi.org/10.1097/0006123-199702000-00038>
- Jabbarli, R., Reinhard, M., Roelz, R., Shah, M., Niesen, W.-D., Kaier, K., Taschner, C., Weyerbrock, A., & Velthoven, V. van. (2015). Early Identification of Individuals at High Risk for Cerebral Infarction after Aneurysmal Subarachnoid Hemorrhage: The BEHAVIOR Score. *Journal of Cerebral Blood Flow & Metabolism*, 35(10), 1587–1592. <https://doi.org/10.1038/jcbfm.2015.81>
- Jäger, H. R., Mansmann, U., Hausmann, O., Partzsch, U., Moseley, I. F., & Taylor, W. J. (2000). MRA versus digital subtraction angiography in acute subarachnoid haemorrhage: a blinded multireader study of prospectively recruited patients. *Neuroradiology*, 42(5), 313–326. <https://doi.org/10.1007/s002340050892>
- Jaja, B. N. R., Cusimano, M. D., Etminan, N., Hanggi, D., Hasan, D., Ilodigwe, D., Lantigua, H., le Roux, P., Lo, B., Louffat-Olivares, A., Mayer, S., Molyneux, A., Quinn, A., Schweizer, T. A., Schenk, T., Spears, J., Todd, M., Torner, J., Vergouwen, M. D. I., ... Macdonald, R. L. (2013). Clinical Prediction Models for Aneurysmal Subarachnoid Hemorrhage: A Systematic Review. *Neurocritical Care*, 18(1), 143–153. <https://doi.org/10.1007/s12028-012-9792-z>
- Jamshidi, M., Rajabian, M., Avery, M. B., Sundararaj, U., Ronsky, J., Belanger, B., Wong, J. H., & Mitha, A. P. (2020). A novel self-expanding primarily bioabsorbable braided flow-diverting stent for aneurysms: initial safety results. *Journal of NeuroInterventional Surgery*, 12(7), 700–705. <https://doi.org/10.1136/neurintsurg-2019-015555>
- Jestaedt, L., Pham, M., Bartsch, A. J., Kunze, E., Roosen, K., Solymosi, L., & Bendszus, M. (2008). THE IMPACT OF BALLOON ANGIOPLASTY ON THE EVOLUTION OF VASOSPASM-RELATED INFARCTION AFTER ANEURYSMAL SUBARACHNOID HEMORRHAGE. *Neurosurgery*, 62(3), 610–617. <https://doi.org/10.1227/01.NEU.0000311351.32904.8B>
- Juvela, S. (1989). Rebleeding from ruptured intracranial aneurysms. *Surgical Neurology*, 32(5), 323–326. [https://doi.org/10.1016/0090-3019\(89\)90133-X](https://doi.org/10.1016/0090-3019(89)90133-X)
- Juvela, S. (2019). Treatment Scoring of Unruptured Intracranial Aneurysms. *Stroke*, 50(9), 2344–2350. <https://doi.org/10.1161/STROKEAHA.119.025599>
- Juvela, S., Poussa, K., & Porras, M. (2001). *Factors Affecting Formation and Growth of Intracranial Aneurysms A Long-Term Follow-Up Study*. <http://ahajournals.org>
- Kabbasch, C., Goertz, L., Siebert, E., Herzberg, M., Borggrefe, J., Dorn, F., & Liebig, T. (2019). Factors that determine aneurysm occlusion after embolization with the Woven EndoBridge (WEB). *Journal of Neurointerventional Surgery*, 11(5), 503–510. <https://doi.org/10.1136/neurintsurg-2018-014361>
- Kabbasch, C., Goertz, L., Siebert, E., Herzberg, M., Borggrefe, J., Krischek, B., Dorn, F., & Liebig, T. (2019). Treatment of Recurrent and Residual Aneurysms with the Woven EndoBridge Device: Analysis of 11 Patients and Review of the Literature. *World Neurosurgery*, 129, e677–e685. <https://doi.org/10.1016/j.wneu.2019.05.248>

- Kabbasch, C., Goertz, L., Siebert, E., Herzberg, M., Borggrefe, J., Krischek, B., Stavrinou, P., Dorn, F., & Liebig, T. (2019). WEB embolization versus stent-assisted coiling: comparison of complication rates and angiographic outcomes. *Journal of NeuroInterventional Surgery*, *11*(8), 812–816. <https://doi.org/10.1136/neurintsurg-2018-014555>
- Kim, J., Han, H. J., Lee, W., Park, S. K., Chung, J., Kim, Y. B., & Park, K. Y. (2021). Safety and Efficacy of Stent-Assisted Coiling of Unruptured Intracranial Aneurysms Using Low-Profile Stents in Small Parent Arteries. *American Journal of Neuroradiology*, *42*(9), 1621–1626. <https://doi.org/10.3174/ajnr.A7196>
- Kim, Y. D., Bang, J. S., Lee, S. U., Jeong, W. J., Kwon, O.-K., Ban, S. P., Kim, T. K., Kim, S. bin, & Oh, C. W. (2018). Long-term outcomes of treatment for unruptured intracranial aneurysms in South Korea: clipping versus coiling. *Journal of NeuroInterventional Surgery*, *10*(12), 1218–1222. <https://doi.org/10.1136/neurintsurg-2018-013757>
- Kim, Y. H., Xu, X., & Lee, J. S. (2010). The Effect of Stent Porosity and Strut Shape on Saccular Aneurysm and its Numerical Analysis with Lattice Boltzmann Method. *Annals of Biomedical Engineering*, *38*(7), 2274–2292. <https://doi.org/10.1007/s10439-010-9994-5>
- Korja, M., Kivisaari, R., Rezai Jahromi, B., & Lehto, H. (2017). Natural History of Ruptured but Untreated Intracranial Aneurysms. *Stroke*, *48*(4), 1081–1084. <https://doi.org/10.1161/STROKEAHA.116.015933>
- Korja, M., Lehto, H., & Juvela, S. (2014). Lifelong Rupture Risk of Intracranial Aneurysms Depends on Risk Factors. *Stroke*, *45*(7), 1958–1963. <https://doi.org/10.1161/STROKEAHA.114.005318>
- Korja, M., Lehto, H., Juvela, S., & Kaprio, J. (2016). *Incidence of subarachnoid hemorrhage is decreasing together with decreasing smoking rates.*
- Korja, M., Silventoinen, K., Laatikainen, T., Jousilahti, P., Salomaa, V., & Kaprio, J. (2013). Cause-specific mortality of 1-year survivors of subarachnoid hemorrhage. *Neurology*, *80*(5), 481–486. <https://doi.org/10.1212/WNL.0b013e31827f0fb5>
- Korja, M., Silventoinen, K., McCarron, P., Zdravkovic, S., Skytthe, A., Haapanen, A., de Faire, U., Pedersen, N. L., Christensen, K., Koskenvuo, M., Kaprio, J., & GenomEUtwin Project. (2010). Genetic epidemiology of spontaneous subarachnoid hemorrhage: Nordic Twin Study. *Stroke*, *41*(11), 2458–2462. <https://doi.org/10.1161/STROKEAHA.110.586420>
- Koroknay-Pál, P., Lehto, H., Niemelä, M., Kivisaari, R., & Hernesniemi, J. (2012). Long-term outcome of 114 children with cerebral aneurysms: Clinical article. *Journal of Neurosurgery: Pediatrics*, *9*(6), 636–645. <https://doi.org/10.3171/2012.2.PEDS11491>
- Koskela, E., Laakso, A., Kivisaari, R., Setälä, K., Hijazy, F., & Hernesniemi, J. (2015). Eye movement abnormalities after a ruptured intracranial aneurysm. *World Neurosurgery*, *83*(3), 362–367. <https://doi.org/10.1016/j.wneu.2014.04.059>
- Kowalski, R. G., Claassen, J., Kreiter, K. T., Bates, J. E., Ostapkovich, N. D., Connolly, E. S., & Mayer, S. A. (2004). Initial misdiagnosis and outcome after subarachnoid hemorrhage. *JAMA*, *291*(7), 866–869. <https://doi.org/10.1001/jama.291.7.866>
- Krag, C. H., Speiser, L., & Dalby, R. B. (2021). Long-term outcomes of endovascular simple coiling versus neurosurgical clipping of unruptured intracranial aneurysms: A systematic review and meta-analysis. *Journal of the Neurological Sciences*, *422*, 117338. <https://doi.org/10.1016/j.jns.2021.117338>
- Kreiter, K. T., Copeland, D., Bernardini, G. L., Bates, J. E., Peery, S., Claassen, J., Du, Y. E., Stern, Y., Connolly, E. S., & Mayer, S. A. (2002). Predictors of cognitive dysfunction after subarachnoid hemorrhage. *Stroke*, *33*(1), 200–208. <https://doi.org/10.1161/hs0102.101080>
- Krings, T., Geibprasert, S., & Lasjaunias, P. L. (2008). Cerebrovascular trauma. *European Radiology*, *18*(8), 1531–1545. <https://doi.org/10.1007/s00330-008-0915-z>
- Krings, T., Mandell, D. M., Kiehl, T. R., Geibprasert, S., Tymianski, M., Alvarez, H., TerBrugge, K. G., & Hans, F. J. (2011). Intracranial aneurysms: From vessel wall pathology to therapeutic approach. In *Nature Reviews Neurology* (Vol. 7, Issue 10, pp. 547–559). <https://doi.org/10.1038/nrneurol.2011.136>

- Kühn, A. L., de Macedo Rodrigues, K., Lozano, J. D., Rex, D. E., Massari, F., Tamura, T., Howk, M., Brooks, C., L'Heureux, J., Gounis, M. J., Wakhloo, A. K., & Puri, A. S. (2017). Use of the Pipeline embolization device for recurrent and residual cerebral aneurysms: a safety and efficacy analysis with short-term follow-up. *Journal of Neurointerventional Surgery*, 9(12), 1208–1213. <https://doi.org/10.1136/neurintsurg-2016-012772>
- Kung, D. K., Policeni, B. A., Capuano, A. W., Rossen, J. D., Jabbour, P. M., Torner, J. C., Howard, M. A., & Hasan, D. (2011). Risk of ventriculostomy-related hemorrhage in patients with acutely ruptured aneurysms treated using stent-assisted coiling. *Journal of Neurosurgery*, 114(4), 1021–1027. <https://doi.org/10.3171/2010.9.JNS10445>
- Lall, R. R., Eddleman, C. S., Bendok, B. R., & Batjer, H. H. (2009). Unruptured intracranial aneurysms and the assessment of rupture risk based on anatomical and morphological factors: sifting through the sands of data. *Neurosurgical Focus*, 26(5), E2. <https://doi.org/10.3171/2009.2.FOCUS0921>
- Lasjaunias, P., Wuppalapati, S., Alvarez, H., Rodesch, G., & Ozanne, A. (2005). Intracranial aneurysms in children aged under 15 years: Review of 59 consecutive children with 75 aneurysms. *Child's Nervous System*, 21(6), 437–450. <https://doi.org/10.1007/s00381-004-1125-x>
- Lawton, M. T., Abla, A. A., Rutledge, W. C., Benet, A., Zador, Z., Rayz, V. L., Saloner, D., & Halbach, V. v. (2016). Bypass Surgery for the Treatment of Dolichoectatic Basilar Trunk Aneurysms: A Work in Progress. *Neurosurgery*, 79(1), 83–99. <https://doi.org/10.1227/NEU.0000000000001175>
- Lawton, M. T., & Vates, G. E. (2017). Subarachnoid Hemorrhage. *New England Journal of Medicine*, 377(3), 257–266. <https://doi.org/10.1056/NEJMcpl605827>
- Lee, V. H., Oh, J. K., Mulvagh, S. L., & Wijedicks, E. F. M. (2006). Mechanisms in Neurogenic Stress Cardiomyopathy After Aneurysmal Subarachnoid Hemorrhage. *Neurocritical Care*, 5(3), 243–249. <https://doi.org/10.1385/NCC:5:3:243>
- Li, K., Barras, C. D., Chandra, R. v., Kok, H. K., Maingard, J. T., Carter, N. S., Russell, J. H., Lai, L., Brooks, M., & Asadi, H. (2019). A Review of the Management of Cerebral Vasospasm After Aneurysmal Subarachnoid Hemorrhage. *World Neurosurgery*, 126, 513–527. <https://doi.org/10.1016/j.wneu.2019.03.083>
- Li, Y.-L., Roalfe, A., Chu, E. Y.-L., Lee, R., & Tsang, A. C. O. (2021). Outcome of Flow Diverters with Surface Modifications in Treatment of Cerebral Aneurysms: Systematic Review and Meta-analysis. *American Journal of Neuroradiology*, 42(2), 327–333. <https://doi.org/10.3174/ajnr.A6919>
- Liang, C. W., Su, K., Liu, J. J., Dogan, A., & Hinson, H. E. (2015). Timing of deep vein thrombosis formation after aneurysmal subarachnoid hemorrhage. *Journal of Neurosurgery*, 123(4), 891–896. <https://doi.org/10.3171/2014.12.JNS141288>
- Limbucci, N., Leone, G., Renieri, L., Nappini, S., Cagnazzo, F., Laiso, A., Muto, M., & Mangiafico, S. (2020). Expanding Indications for Flow Diverters: Distal Aneurysms, Bifurcation Aneurysms, Small Aneurysms, Previously Coiled Aneurysms and Clipped Aneurysms, and Carotid Cavernous Fistulas. *Neurosurgery*, 86(Supplement\_1), S85–S94. <https://doi.org/10.1093/neuros/nyz334>
- Lin, N., Cahill, K. S., Frerichs, K. U., Friedlander, R. M., & Claus, E. B. (2018). Treatment of ruptured and unruptured cerebral aneurysms in the USA: a paradigm shift. *Journal of NeuroInterventional Surgery*, 10(Suppl 1), i69–i76. <https://doi.org/10.1136/jnis.2011.004978.rep>
- Lindgren, A. E., Koivisto, T., Björkman, J., von Und Zu Fraunberg, M., Helin, K., Jääskeläinen, J. E., & Frösen, J. (2016). Irregular Shape of Intracranial Aneurysm Indicates Rupture Risk Irrespective of Size in a Population-Based Cohort. *Stroke*, 47(5), 1219–1226. <https://doi.org/10.1161/STROKEAHA.115.012404>
- Lobsien, D., Clajus, C., Behme, D., Ernst, M., Riedel, C. H., Abu-Fares, O., Götz, F. G., Fiorella, D., & Klisch, J. (2021). Aneurysm Treatment in Acute SAH with Hydrophilic-Coated Flow Diverters under Single-Antiplatelet Therapy: A 3-Center Experience. *American Journal of Neuroradiology*, 42(3), 508–515. <https://doi.org/10.3174/ajnr.A6942>

- Lovelock, C. E., Rinkel, G. J. E., & Rothwell, P. M. (2010). Time trends in outcome of subarachnoid hemorrhage: Population-based study and systematic review. *Neurology*, *74*(19), 1494–1501. <https://doi.org/10.1212/WNL.0b013e3181dd42b3>
- M Vlak, M. H., Algra, A., Brandenburg, R., E Rinkel, G. J., M Vlak, M. H., Algra, A., Brandenburg, R., & E Rinkel, G. J. (2011). Prevalence of unruptured intracranial aneurysms, with emphasis on sex, age, comorbidity, country, and time period: a systematic review and meta-analysis. *The Lancet Neurology*, *10*, 626–636. <https://doi.org/10.1016/S1474>
- Macdonald, R. L. (2014). Delayed neurological deterioration after subarachnoid haemorrhage. In *Nature Reviews Neurology* (Vol. 10, Issue 1, pp. 44–58). <https://doi.org/10.1038/nrneurol.2013.246>
- Madaelil, T. P., Moran, C. J., Cross, D. T., & Kansagra, A. P. (2017). Flow Diversion in Ruptured Intracranial Aneurysms: A Meta-Analysis. *American Journal of Neuroradiology*, *38*(3), 590–595. <https://doi.org/10.3174/ajnr.A5030>
- Mangrum, W. I., Huston, J., Link, M. J., Wiebers, D. O., McClelland, R. L., Christianson, T. J. H., & Flemming, K. D. (2005). Enlarging vertebrobasilar nonsaccular intracranial aneurysms: frequency, predictors, and clinical outcome of growth. *Journal of Neurosurgery*, *102*(1), 72–79. <https://doi.org/10.3171/jns.2005.102.1.0072>
- Manning, N. W., Cheung, A., Phillips, T. J., & Wenderoth, J. D. (2019). Pipeline shield with single antiplatelet therapy in aneurysmal subarachnoid haemorrhage: multicentre experience. *Journal of NeuroInterventional Surgery*, *11*(7), 694–698. <https://doi.org/10.1136/neurintsurg-2018-014363>
- Maragos, G. A., Dmytriw, A. A., Salem, M. M., Tutino, V. M., Meng, H., Cognard, C., Machi, P., Krings, T., & Mendes Pereira, V. (2020). Overview of Different Flow Diverters and Flow Dynamics. *Neurosurgery*, *86*(Supplement\_1), S21–S34. <https://doi.org/10.1093/neuros/nyz323>
- Martínez-Galdámez, M., Lamin, S. M., Lagios, K. G., Liebig, T., Ciceri, E. F., Chapot, R., Stockx, L., Chavda, S., Kabbasch, C., Farago, G., Nordmeyer, H., Boulanger, T., Piano, M., & Boccardi, E. P. (2017). Periprocedural outcomes and early safety with the use of the Pipeline Flex Embolization Device with Shield Technology for unruptured intracranial aneurysms: preliminary results from a prospective clinical study. *Journal of Neurointerventional Surgery*, *9*(8), 772–776. <https://doi.org/10.1136/neurintsurg-2016-012896>
- Martínez-Galdámez, M., Romance, A., Vega, P., Vega, A., Caniego, J. L., Paul, L., Linfante, I., & Dabus, G. (2015). Pipeline endovascular device for the treatment of intracranial aneurysms at the level of the circle of Willis and beyond: multicenter experience. *Journal of Neurointerventional Surgery*, *7*(11), 816–823. <https://doi.org/10.1136/neurintsurg-2014-011355>
- Mascitelli, J. R., Moyle, H., Oermann, E. K., Polykarpou, M. F., Patel, A. A., Doshi, A. H., Gologorsky, Y., Bederson, J. B., & Patel, A. B. (2015). An update to the Raymond–Roy Occlusion Classification of intracranial aneurysms treated with coil embolization. *Journal of NeuroInterventional Surgery*, *7*(7), 496–502. <https://doi.org/10.1136/neurintsurg-2014-011258>
- Maus, V., Mpotsaris, A., Dorn, F., Möhlenbruch, M., Borggrefe, J., Stavrinou, P., Abdullayev, N., Barnikol, U. B., Liebig, T., & Kabbasch, C. (2018). The Use of Flow Diverter in Ruptured, Dissecting Intracranial Aneurysms of the Posterior Circulation. *World Neurosurgery*, *111*, e424–e433. <https://doi.org/10.1016/j.wneu.2017.12.095>
- Maus, V., Weber, W., Berlis, A., Maurer, C., & Fischer, S. (2021). Initial Experience with Surpass Evolve Flow Diverter in the Treatment of Intracranial Aneurysms. *Clinical Neuroradiology*, *31*(3), 681–689. <https://doi.org/10.1007/s00062-020-00972-5>
- Meurer, W. J., Walsh, B., Vilke, G. M., & Coyne, C. J. (2016). Clinical Guidelines for the Emergency Department Evaluation of Subarachnoid Hemorrhage. *The Journal of Emergency Medicine*, *50*(4), 696–701. <https://doi.org/10.1016/j.jemermed.2015.07.048>
- Meyers, P. M., Coon, A. L., Kan, P. T., Wakhloo, A. K., & Hanel, R. A. (2019). SCENT Trial. *Stroke*, *50*(6), 1473–1479. <https://doi.org/10.1161/STROKEAHA.118.024135>
- Meyers, P. M., Schumacher, H. C., Higashida, R. T., Derdeyn, C. P., Nesbit, G. M., Sacks, D., Wechsler, L. R., Bederson, J. B., Lavine, S. D., & Rasmussen, P. (2009). Reporting standards for

- endovascular repair of saccular intracranial cerebral aneurysms. In *Stroke* (Vol. 40, Issue 5). <https://doi.org/10.1161/STROKEAHA.108.527572>
- Mizutani, T., Miki, Y., Kojima, H., & Suzuki, H. (1999). Proposed classification of nonatherosclerotic cerebral fusiform and dissecting aneurysms. *Neurosurgery*, *45*(2), 253–259; discussion 259–60. <https://doi.org/10.1097/00006123-199908000-00010>
- Mocco, J., Ransom, E. R., Komotar, R. J., Schmidt, J. M., Sciacca, R. R., Mayer, S. A., & Connolly, E. S. (2006). Preoperative Prediction of Long-term Outcome in Poor-grade Aneurysmal Subarachnoid Hemorrhage. *Neurosurgery*, *59*(3), 529–538. <https://doi.org/10.1227/01.NEU.0000228680.22550.A2>
- Molyneux, A. J., Birks, J., Clarke, A., Sneade, M., & Kerr, R. S. C. (2015). The durability of endovascular coiling versus neurosurgical clipping of ruptured cerebral aneurysms: 18 year follow-up of the UK cohort of the International Subarachnoid Aneurysm Trial (ISAT). *The Lancet*, *385*(9969), 691–697. [https://doi.org/10.1016/S0140-6736\(14\)60975-2](https://doi.org/10.1016/S0140-6736(14)60975-2)
- Molyneux, A. J., Kerr, R. S., Birks, J., Ramzi, N., Yarnold, J., Sneade, M., & Rischmiller, J. (2009). Risk of recurrent subarachnoid haemorrhage, death, or dependence and standardised mortality ratios after clipping or coiling of an intracranial aneurysm in the International Subarachnoid Aneurysm Trial (ISAT): long-term follow-up. *The Lancet Neurology*, *8*(5), 427–433. [https://doi.org/10.1016/S1474-4422\(09\)70080-8](https://doi.org/10.1016/S1474-4422(09)70080-8)
- Molyneux, A. J., Kerr, R. S., Yu, L.-M., Clarke, M., Sneade, M., Yarnold, J. A., & Sandercock, P. (2005). International subarachnoid aneurysm trial (ISAT) of neurosurgical clipping versus endovascular coiling in 2143 patients with ruptured intracranial aneurysms: a randomised comparison of effects on survival, dependency, seizures, rebleeding, subgroups, and aneurysm occlusion. *The Lancet*, *366*(9488), 809–817. [https://doi.org/10.1016/S0140-6736\(05\)67214-5](https://doi.org/10.1016/S0140-6736(05)67214-5)
- Moret, J., Cognard, C., Weill, A., Castaing, L., & Rey, A. (1997). The “Remodelling Technique” in the Treatment of Wide Neck Intracranial Aneurysms. Angiographic Results and Clinical Follow-up in 56 Cases. *Interventional Neuroradiology: Journal of Peritherapeutic Neuroradiology, Surgical Procedures and Related Neurosciences*, *3*(1), 21–35. <https://doi.org/10.1177/159101999700300103>
- Müller, T. B., Vik, A., Romundstad, P. R., & Sandvei, M. S. (2019). Risk Factors for Unruptured Intracranial Aneurysms and Subarachnoid Hemorrhage in a Prospective Population-Based Study. *Stroke*, *50*(10), 2952–2955. <https://doi.org/10.1161/STROKEAHA.119.025951>
- Murayama, Y., Takao, H., Ishibashi, T., Saguchi, T., Ebara, M., Yuki, I., Arakawa, H., Irie, K., Urashima, M., & Molyneux, A. J. (2016). Risk Analysis of Unruptured Intracranial Aneurysms. *Stroke*, *47*(2), 365–371. <https://doi.org/10.1161/STROKEAHA.115.010698>
- Nakatomi, H., Kiyofuji, S., Ono, H., Tanaka, M., Kamiyama, H., Takizawa, K., Imai, H., Saito, N., Shiokawa, Y., Morita, A., Flemming, K. D., & Link, M. J. (2020). Giant Fusiform and Dolichoectatic Aneurysms of the Basilar Trunk and Vertebrobasilar Junction—Clinicopathological and Surgical Outcome. *Neurosurgery*, *88*(1), 82–95. <https://doi.org/10.1093/neuros/nyaa317>
- Navarro, R., Brown, B. L., Beier, A., Ranalli, N., Aldana, P., & Hanel, R. A. (2015). Flow diversion for complex intracranial aneurysms in young children. *Journal of Neurosurgery: Pediatrics*, *15*(3), 276–281. <https://doi.org/10.3171/2014.9.PEDS14333>
- Nieuwkamp, D. J., Setz, L. E., Algra, A., Linn, F. H. H., de Rooij, N. K., & Rinkel, G. J. E. (2009). Changes in case fatality of aneurysmal subarachnoid haemorrhage over time, according to age, sex, and region: a meta-analysis. *The Lancet. Neurology*, *8*(7), 635–642. [https://doi.org/10.1016/S1474-4422\(09\)70126-7](https://doi.org/10.1016/S1474-4422(09)70126-7)
- Noble, A. J., Baisch, S., Mendelow, A. D., Allen, L., Kane, P., & Schenk, T. (2008). Posttraumatic stress disorder explains reduced quality of life in subarachnoid hemorrhage patients in both the short and long term. *Neurosurgery*, *63*(6), 1095–1104; discussion 1004–5. <https://doi.org/10.1227/01.NEU.0000327580.91345.78>



- Ohkuma, H., Tsurutani, H., & Suzuki, S. (2001). Incidence and Significance of Early Aneurysmal Rebleeding Before Neurosurgical or Neurological Management. *Stroke*, *32*(5), 1176–1180. <https://doi.org/10.1161/01.STR.32.5.1176>
- Ojha, M., Finnis, M. E., Heckelmann, M., Raith, E. P., Moodie, S., Chapman, M. J., Reddi, B., & Maiden, M. J. (2020). Outcomes following grade V subarachnoid haemorrhage: A single-centre retrospective study. *Anaesthesia and Intensive Care*, *48*(4), 289–296. <https://doi.org/10.1177/0310057X20927033>
- O’Kelly, C. J., Krings, T., Fiorella, D., & Marotta, T. R. (2010). A Novel Grading Scale for the Angiographic Assessment of Intracranial Aneurysms Treated Using Flow Diverting Stents. *Interventional Neuroradiology*, *16*(2), 133–137. <https://doi.org/10.1177/159101991001600204>
- O’Neill, A. H., Chandra, R. v., & Lai, L. T. (2017). Safety and effectiveness of microsurgical clipping, endovascular coiling, and stent assisted coiling for unruptured anterior communicating artery aneurysms: a systematic analysis of observational studies. *Journal of NeuroInterventional Surgery*, *9*(8), 761–765. <https://doi.org/10.1136/neurintsurg-2016-012629>
- Orru, E., Rice, H., de Villiers, L., Klostranec, J. M., Wakhloo, A. K., Coon, A. L., Radovanovic, I., Kortman, H., Bhatia, K. D., Krings, T., & Pereira, V. M. (2020). First clinical experience with the new Surpass Evolve flow diverter: technical and clinical considerations. *Journal of NeuroInterventional Surgery*, *12*(10), 974–980. <https://doi.org/10.1136/neurintsurg-2019-015734>
- Park, J. H., Kim, J. E., Sheen, S. H., Jung, C. K., Kwon, B. J., Kwon, O.-K., Oh, C. W., Han, M. H., & Han, D. H. (2008). Intraarterial abciximab for treatment of thromboembolism during coil embolization of intracranial aneurysms: outcome and fatal hemorrhagic complications. *Journal of Neurosurgery*, *108*(3), 450–457. <https://doi.org/10.3171/JNS/2008/108/3/0450>
- Peluso, J. P. P., van Rooij, W. J., Sluzewski, M., & Beute, G. N. (2008). A new self-expandable nitinol stent for the treatment of wide-neck aneurysms: initial clinical experience. *AJNR. American Journal of Neuroradiology*, *29*(7), 1405–1408. <https://doi.org/10.3171/ajnr.A1104>
- Perry, J. J., Stiell, I. G., Sivilotti, M. L. A., Bullard, M. J., Émond, M., Symington, C., Sutherland, J., Worster, A., Hohl, C., Lee, J. S., Eisenhauer, M. A., Mortensen, M., Mackey, D., Pauls, M., Lesiuk, H., & Wells, G. A. (2011). Sensitivity of computed tomography performed within six hours of onset of headache for diagnosis of subarachnoid haemorrhage: Prospective cohort study. *BMJ (Online)*, *343*(7817). <https://doi.org/10.1136/bmj.d4277>
- Peschillo, S., Cannizzaro, D., Caporlingua, A., & Missori, P. (2016). A Systematic Review and Meta-Analysis of Treatment and Outcome of Blister-Like Aneurysms. *AJNR. American Journal of Neuroradiology*, *37*(5), 856–861. <https://doi.org/10.3174/ajnr.A4606>
- Phan, K., Huo, Y. R., Jia, F., Phan, S., Rao, P. J., Mobbs, R. J., & Mortimer, A. M. (2016). Meta-analysis of stent-assisted coiling versus coiling-only for the treatment of intracranial aneurysms. *Journal of Clinical Neuroscience: Official Journal of the Neurosurgical Society of Australasia*, *31*, 15–22. <https://doi.org/10.1016/j.jocn.2016.01.035>
- Phatouros, C. C., Sasaki, T. Y., Higashida, R. T., Malek, A. M., Meyers, P. M., Dowd, C. F., & Halbach, V. v. (2000). Stent-supported coil embolization: the treatment of fusiform and wide-neck aneurysms and pseudoaneurysms. *Neurosurgery*, *47*(1), 107–113; discussion 113-5. <https://doi.org/10.1097/00006123-200007000-00023>
- Pickard, J. D., Murray, G. D., Illingworth, R., Shaw, M. D., Teasdale, G. M., Foy, P. M., Humphrey, P. R., Lang, D. A., Nelson, R., & Richards, P. (1989). Effect of oral nimodipine on cerebral infarction and outcome after subarachnoid haemorrhage: British aneurysm nimodipine trial. *BMJ*, *298*(6674), 636–642. <https://doi.org/10.1136/bmj.298.6674.636>
- Pierot, L., Bannery, C., Batchinsky-Parrou, V., Kleiber, J.-C., Soize, S., & Litre, C. F. (2019). Clipping of recanalized intracerebral aneurysms initially treated by the Woven EndoBridge device. *Journal of NeuroInterventional Surgery*, *11*(8), 807–811. <https://doi.org/10.1136/neurintsurg-2019-014903>
- Pierot, L., Barbe, C., Herbretreau, D., Gauvrit, J.-Y., Januel, A.-C., Bala, F., Ricolfi, F., Desal, H., Velasco, S., Aggour, M., Chabert, E., Sedat, J., Trystram, D., Marnat, G., Gallas, S., Rodesch, G.,

- Clarençon, F., Papagiannaki, C., White, P., & Spelle, L. (2020). Rebleeding and bleeding in the year following intracranial aneurysm coiling: analysis of a large prospective multicenter cohort of 1140 patients—Analysis of Recanalization after Endovascular Treatment of Intracranial Aneurysm (ARETA) Study. *Journal of NeuroInterventional Surgery*, neurintsurg-2020-015971. <https://doi.org/10.1136/neurintsurg-2020-015971>
- Pierot, L., Cognard, C., Anxionnat, R., Ricolfi, F., & CLARITY Investigators. (2011). Remodeling technique for endovascular treatment of ruptured intracranial aneurysms had a higher rate of adequate postoperative occlusion than did conventional coil embolization with comparable safety. *Radiology*, 258(2), 546–553. <https://doi.org/10.1148/radiol.10100894>
- Pierot, L., Cognard, C., Spelle, L., & Moret, J. (2010). Safety and Efficacy of the Remodelling Technique in the Endovascular Treatment of Ruptured and Unruptured Intracranial Aneurysms: Analysis in 2 Prospective Series of Patients (CLARITY and ATENA). *Neurosurgery*, 67(2), 540–541. <https://doi.org/10.1227/01.NEU.0000386986.57991.0D>
- Pierot, L., Cognard, C., Spelle, L., & Moret, J. (2012). Safety and efficacy of balloon remodeling technique during endovascular treatment of intracranial aneurysms: critical review of the literature. *AJNR. American Journal of Neuroradiology*, 33(1), 12–15. <https://doi.org/10.3174/ajnr.A2403>
- Pierot, L., Moret, J., Barreau, X., Szikora, I., Herbreteau, D., Turjman, F., Holtmannspötter, M., Januel, A.-C., Costalat, V., Fiehler, J., Klisch, J., Gauvrit, J.-Y., Weber, W., Desal, H., Velasco, S., Liebig, T., Stockx, L., Berkefeld, J., Molyneux, A., ... Spelle, L. (2018). Safety and efficacy of aneurysm treatment with WEB in the cumulative population of three prospective, multicenter series. *Journal of NeuroInterventional Surgery*, 10(6), 553–559. <https://doi.org/10.1136/neurintsurg-2017-013448>
- Pierot, L., Moret, J., Barreau, X., Szikora, I., Herbreteau, D., Turjman, F., Holtmannspötter, M., Januel, A.-C., Costalat, V., Fiehler, J., Klisch, J., Gauvrit, J.-Y., Weber, W., Desal, H., Velasco, S., Liebig, T., Stockx, L., Berkefeld, J., Molyneux, A., ... Spelle, L. (2020). Aneurysm Treatment With Woven EndoBridge in the Cumulative Population of 3 Prospective, Multicenter Series: 2-Year Follow-Up. *Neurosurgery*, 87(2), 357–367. <https://doi.org/10.1093/neuros/nyz557>
- Pierot, L., Portefaix, C., Rodriguez-Régent, C., Gallas, S., Meder, J.-F., & Oppenheim, C. (2013). Role of MRA in the detection of intracranial aneurysm in the acute phase of subarachnoid hemorrhage. *Journal of Neuroradiology*, 40(3), 204–210. <https://doi.org/10.1016/j.neurad.2013.03.004>
- Pierot, L., Spelle, L., Leclerc, X., Cognard, C., Bonafé, A., & Moret, J. (2009). Endovascular treatment of unruptured intracranial aneurysms: comparison of safety of remodeling technique and standard treatment with coils. *Radiology*, 251(3), 846–855. <https://doi.org/10.1148/radiol.2513081056>
- Pierot, L., Spelle, L., Molyneux, A., & Byrne, J. (2015). Clinical and anatomical follow-up in patients with aneurysms treated with the WEB device: 1-year follow-up report in the cumulated population of 2 prospective, multicenter series (WEBCAST and French Observatory). *Neurosurgery*. <https://doi.org/10.1227/NEU.0000000000001106>
- Pierot, L., Szikora, I., Barreau, X., Holtmannspötter, M., Spelle, L., Herbreteau, D., Fiehler, J., Costalat, V., Klisch, J., Januel, A.-C., Weber, W., Liebig, T., Stockx, L., Berkefeld, J., Moret, J., Molyneux, A., & Byrne, J. (2021). Aneurysm treatment with WEB in the cumulative population of two prospective, multicenter series: 3-year follow-up. *Journal of NeuroInterventional Surgery*, 13(4), 363–368. <https://doi.org/10.1136/neurintsurg-2020-016151>
- Piotin, M., Biondi, A., Sourour, N., Mounayer, C., Jaworski, M., Mangiafico, S., Andersson, T., Söderman, M., Goffette, P., Anxionnat, R., & Blanc, R. (2018). The LUNA aneurysm embolization system for intracranial aneurysm treatment: short-term, mid-term and long-term clinical and angiographic results. *Journal of Neurointerventional Surgery*, 10(12), e34. <https://doi.org/10.1136/neurintsurg-2018-013767>
- Piotin, M., Blanc, R., Spelle, L., Mounayer, C., Piantino, R., Schmidt, P. J., & Moret, J. (2010). Stent-Assisted Coiling of Intracranial Aneurysms. *Stroke*, 41(1), 110–115. <https://doi.org/10.1161/STROKEAHA.109.558114>

- Qureshi, A. I., Suarez, J. I., Parekh, P. D., Sung, G., Geocadin, R., Bhardwaj, A., Tamargo, R. J., & Ulatowski, J. A. (1998). Risk Factors for Multiple Intracranial Aneurysms. *Neurosurgery*, *43*(1), 22–26. <https://doi.org/10.1097/00006123-199807000-00013>
- Raaymakers, T. W. M., Rinkel, G. J. E., Limburg, M., & Algra, A. (1998). Mortality and Morbidity of Surgery for Unruptured Intracranial Aneurysms. *Stroke*, *29*(8), 1531–1538. <https://doi.org/10.1161/01.STR.29.8.1531>
- Rabinov, J. D., Hellinger, F. R., Morris, P. P., Ogilvy, C. S., & Putman, C. M. (2003). Endovascular management of vertebrobasilar dissecting aneurysms. *AJNR. American Journal of Neuroradiology*, *24*(7), 1421–1428.
- Rahman, M., & Friedman, W. A. (2009). HYPONATREMIA IN NEUROSURGICAL PATIENTS. *Neurosurgery*, *65*(5), 925–936. <https://doi.org/10.1227/01.NEU.0000358954.62182.B3>
- Raper, D. M. S., Starke, R. M., Komotar, R. J., Allan, R., & Connolly, E. S. (2013). Seizures After Aneurysmal Subarachnoid Hemorrhage: A Systematic Review of Outcomes. *World Neurosurgery*, *79*(5–6), 682–690. <https://doi.org/10.1016/j.wneu.2012.08.006>
- Raslan, A. M., Fields, J. D., & Bhardwaj, A. (2010). Prophylaxis for Venous Thrombo-Embolism in Neurocritical Care: A Critical Appraisal. *Neurocritical Care*, *12*(2), 297–309. <https://doi.org/10.1007/s12028-009-9316-7>
- Rautalin, I., Juvela, S., Macdonald, R. L., & Korja, M. (2022). Body Mass Index and the Risk of Poor Outcome in Surgically Treated Patients With Good-Grade Aneurysmal Subarachnoid Hemorrhage. *Neurosurgery*, *90*(6), 816–822. <https://doi.org/10.1227/neu.0000000000001931>
- Ray, W. Z., Strom, R. G., Blackburn, S. L., Ashley, W. W., Sicard, G. A., & Rich, K. M. (2009). Incidence of deep venous thrombosis after subarachnoid hemorrhage. *Journal of Neurosurgery*, *110*(5), 1010–1014. <https://doi.org/10.3171/2008.9.JNS08107>
- Rincon, F., Gordon, E., Starke, R. M., Buitrago, M. M., Fernandez, A., Schmidt, J. M., Claassen, J., Wartenberg, K. E., Frontera, J., Seder, D. B., Palestrant, D., Connolly, E. S., Lee, K., Mayer, S. A., & Badjatia, N. (2010). Predictors of long-term shunt-dependent hydrocephalus after aneurysmal subarachnoid hemorrhage. *Journal of Neurosurgery*, *113*(4), 774–780. <https://doi.org/10.3171/2010.2.JNS09376>
- Rincon, F., Rossenwasser, R. H., & Dumont, A. (2013). The Epidemiology of Admissions of Nontraumatic Subarachnoid Hemorrhage in the United States. *Neurosurgery*, *73*(2), 217–223. <https://doi.org/10.1227/01.neu.0000430290.93304.33>
- Rinne, J., Hernesniemi, J., Puranen, M., & Saari, T. (1994). Multiple intracranial aneurysms in a defined population: prospective angiographic and clinical study. *Neurosurgery*, *35*(5), 803–808. <https://doi.org/10.1227/00006123-199411000-00001>
- Riva, M., Amin-Hanjani, S., Giussani, C., de Witte, O., & Bruneau, M. (2018). Indocyanine Green Videoangiography in Aneurysm Surgery: Systematic Review and Meta-Analysis. *Neurosurgery*, *83*(2), 166–180. <https://doi.org/10.1093/neuros/nyx387>
- Romani, R., Lehto, H., Laakso, A., Horcajadas, A., Kivisaari, R., Fraunberg, M., Niemelä, M., Rinne, J., & Hernesniemi, J. (2011). Microsurgical technique for previously coiled aneurysms. In *Journal of Neurosurgical Sciences*.
- Ronkainen, A., Hernesniemi, J., Puranen, M., Niemitukia, L., Vanninen, R., Rynänen, M., Kuivaniemi, H., & Tromp, G. (1997). Familial intracranial aneurysms. *Lancet (London, England)*, *349*(9049), 380–384. [https://doi.org/10.1016/S0140-6736\(97\)80009-8](https://doi.org/10.1016/S0140-6736(97)80009-8)
- Rouchaud, A., Brinjikji, W., Cloft, H. J., & Kallmes, D. F. (2015). Endovascular Treatment of Ruptured Blister-Like Aneurysms: A Systematic Review and Meta-Analysis with Focus on Deconstructive versus Reconstructive and Flow-Diverter Treatments. *AJNR. American Journal of Neuroradiology*, *36*(12), 2331–2339. <https://doi.org/10.3174/ajnr.A4438>
- Roy, D., Milot, G., & Raymond, J. (2001). Endovascular Treatment of Unruptured Aneurysms. *Stroke*, *32*(9), 1998–2004. <https://doi.org/10.1161/hs0901.095600>
- Sadan, O., Waddel, H., Moore, R., Feng, C., Mei, Y., Pearce, D., Kraft, J., Pimentel, C., Mathew, S., Akbik, F., Ameli, P., Taylor, A., Danyluk, L., Martin, K. S., Garner, K., Kolenda, J., Pujari, A.,

- Asbury, W., Jaja, B. N. R., ... Samuels, O. (2021). Does intrathecal nicardipine for cerebral vasospasm following subarachnoid hemorrhage correlate with reduced delayed cerebral ischemia? A retrospective propensity score-based analysis. *Journal of Neurosurgery*, 1–10. <https://doi.org/10.3171/2020.12.JNS203673>
- Sadasivan, C., & Fiorella, D. (2020). Preliminary in vitro angiographic comparison of the flow diversion behavior of Evolve and Pipeline devices. *Journal of NeuroInterventional Surgery*, 12(6), 616–620. <https://doi.org/10.1136/neurintsurg-2019-015455>
- Samuels, O. B., Sadan, O., Feng, C., Martin, K., Medani, K., Mei, Y., & Barrow, D. L. (2021). Aneurysmal Subarachnoid Hemorrhage: Trends, Outcomes, and Predictions From a 15-Year Perspective of a Single Neurocritical Care Unit. *Neurosurgery*, 88(3), 574–583. <https://doi.org/10.1093/neuros/nyaa465>
- Samuels, O., Webb, A., Culler, S., Martin, K., & Barrow, D. (2011). Impact of a Dedicated Neurocritical Care Team in Treating Patients with Aneurysmal Subarachnoid Hemorrhage. *Neurocritical Care*, 14(3), 334–340. <https://doi.org/10.1007/s12028-011-9505-z>
- Sen, J., Belli, A., Albon, H., Morgan, L., Petzold, A., & Kitchen, N. (2003). Triple-H therapy in the management of aneurysmal subarachnoid haemorrhage. *The Lancet Neurology*, 2(10), 614–621. [https://doi.org/10.1016/S1474-4422\(03\)00531-3](https://doi.org/10.1016/S1474-4422(03)00531-3)
- Serrone, J. C., Gozal, Y. M., Grossman, A. W., Andaluz, N., Abruzzo, T., Zuccarello, M., & Ringer, A. (2014). Vertebrobasilar fusiform aneurysms. *Neurosurgery Clinics of North America*, 25(3), 471–484. <https://doi.org/10.1016/j.nec.2014.04.006>
- Shapiro, M., Babb, J., Becske, T., & Nelson, P. K. (2008). Safety and efficacy of adjunctive balloon remodeling during endovascular treatment of intracranial aneurysms: a literature review. *AJNR. American Journal of Neuroradiology*, 29(9), 1777–1781. <https://doi.org/10.3174/ajnr.A1216>
- Shapiro, M., Becske, T., Sahlein, D., Babb, J., & Nelson, P. K. (2012). Stent-Supported Aneurysm Coiling: A Literature Survey of Treatment and Follow-Up. *American Journal of Neuroradiology*, 33(1), 159–163. <https://doi.org/10.3174/ajnr.A2719>
- Sluzewski, M., van Rooij, W. J., Slob, M. J., Bescós, J. O., Slump, C. H., & Wijnalda, D. (2004). Relation between aneurysm volume, packing, and compaction in 145 cerebral aneurysms treated with coils. *Radiology*, 231(3), 653–658. <https://doi.org/10.1148/radiol.2313030460>
- Smith, A. M., Clark, P. R., Winter, K. A., Smalley, Z. P., Duke, S. M., Dedwylder, M., & Washington, C. W. (2021). The effect of prophylactic antiepileptic medications in aneurysmal subarachnoid hemorrhage patients: A retrospective review. *Clinical Neurology and Neurosurgery*, 205, 106633. <https://doi.org/10.1016/j.clineuro.2021.106633>
- Solanki, C., Pandey, P., & Rao, K. V. L. N. (2016). Predictors of aneurysmal rebleed before definitive surgical or endovascular management. *Acta Neurochirurgica*, 158(6), 1037–1044. <https://doi.org/10.1007/s00701-016-2784-6>
- Spelle, L., Herbretreau, D., Caroff, J., Barreau, X., Ferré, J.-C., Fiehler, J., Januel, A.-C., Costalat, V., Liebig, T., Bourcier, R., Möhlenbruch, M., Berkefeld, J., Weber, W., Mihalea, C., Ikka, L., Ozanne, A., Cognard, C., Narata, A. P., Bibi, R. E., ... Pierot, L. (2021). CLinical Assessment of WEB device in Ruptured aneurYSms (CLARYS): results of 1-month and 1-year assessment of rebleeding protection and clinical safety in a multicenter study. *Journal of NeuroInterventional Surgery*, neurintsurg-2021-017416. <https://doi.org/10.1136/neurintsurg-2021-017416>
- Spetzler, R. F., McDougall, C. G., Zabramski, J. M., Albuquerque, F. C., Hills, N. K., Nakaji, P., Karis, J. P., & Wallace, R. C. (2020). Ten-year analysis of saccular aneurysms in the Barrow Ruptured Aneurysm Trial. *Journal of Neurosurgery*, 132(3), 771–776. <https://doi.org/10.3171/2018.8.JNS181846>
- Steiner, T., Juvela, S., Unterberg, A., Jung, C., Forsting, M., & Rinkel, G. (2013). European Stroke Organization Guidelines for the Management of Intracranial Aneurysms and Subarachnoid Haemorrhage. *Cerebrovascular Diseases*, 35(2), 93–112. <https://doi.org/10.1159/000346087>
- Stienen, M. N., Germans, M., Burkhardt, J.-K., Neidert, M. C., Fung, C., Bervini, D., Zumofen, D., Roethlisberger, M., Marbacher, S., Maduri, R., Robert, T., Seule, M. A., Bijlenga, P., Schaller, K.,

- Fandino, J., Smoll, N. R., Maldaner, N., Finkenstädt, S., Esposito, G., ... Corniola, M. (2018). Predictors of In-Hospital Death After Aneurysmal Subarachnoid Hemorrhage. *Stroke*, *49*(2), 333–340. <https://doi.org/10.1161/STROKEAHA.117.019328>
- Sughrue, M. E., Saloner, D., Rayz, V. L., & Lawton, M. T. (2011). Giant Intracranial Aneurysms: Evolution of Management in a Contemporary Surgical Series. *Neurosurgery*, *69*(6), 1261–1271. <https://doi.org/10.1227/NEU.0b013e31822bb8a6>
- Tähtinen, O. I., Manninen, H. I., Vanninen, R. L., Rautio, R., Haapanen, A., Seppänen, J., Niskakangas, T., Rinne, J., & Keski-Nisula, L. (2013). Stent-assisted embolization of recurrent or residual intracranial aneurysms. *Neuroradiology*. <https://doi.org/10.1007/s00234-013-1234-x>
- Tähtinen, O. I., Vanninen, R. L., Manninen, H. I., Rautio, R., Haapanen, A., Niskakangas, T., Rinne, J., & Keski-Nisula, L. (2009). Wide-necked Intracranial Aneurysms: Treatment with Stent-assisted Coil Embolization during Acute (<72 Hours) Subarachnoid Hemorrhage—Experience in 61 Consecutive Patients. *Radiology*, *253*(1), 199–208. <https://doi.org/10.1148/radiol.2531081923>
- Talamonti, G., Nichelatti, M., al Mashni, A. A., & D'Aliberti, G. (2016). Life-Threatening Cerebral Hematoma Owing to Aneurysm Rupture. *World Neurosurgery*, *85*, 215–227. <https://doi.org/10.1016/j.wneu.2015.08.082>
- Tang, C., Zhang, T.-S., & Zhou, L.-F. (2014). Risk Factors for Rebleeding of Aneurysmal Subarachnoid Hemorrhage: A Meta-Analysis. *PLoS ONE*, *9*(6), e99536. <https://doi.org/10.1371/journal.pone.0099536>
- Tanno, Y., Homma, M., Oinuma, M., Kodama, N., & Ymamoto, T. (2007). Rebleeding from ruptured intracranial aneurysms in North Eastern Province of Japan. A cooperative study. *Journal of the Neurological Sciences*, *258*(1–2), 11–16. <https://doi.org/10.1016/j.jns.2007.01.074>
- ten Brinck, M. F. M., Jäger, M., de Vries, J., Grotenhuis, J. A., Aquarius, R., Mørkve, S. H., Rautio, R., Numminen, J., Raj, R., Wakhloo, A. K., Puri, A. S., Taschner, C. A., & Boogaarts, H. D. (2020). Flow diversion treatment for acutely ruptured aneurysms. *Journal of Neurointerventional Surgery*, *12*(3), 283–288. <https://doi.org/10.1136/neurintsurg-2019-015077>
- The Natural Course of Unruptured Cerebral Aneurysms in a Japanese Cohort. (2012). *New England Journal of Medicine*, *366*(26), 2474–2482. <https://doi.org/10.1056/NEJMoa1113260>
- Thompson, B. G., Brown, R. D., Amin-Hanjani, S., Broderick, J. P., Cockroft, K. M., Connolly, E. S., Duckwiler, G. R., Harris, C. C., Howard, V. J., Johnston, S. C. (Clay), Meyers, P. M., Molyneux, A., Ogilvy, C. S., Ringer, A. J., & Torner, J. (2015). Guidelines for the Management of Patients With Unruptured Intracranial Aneurysms. *Stroke*, *46*(8), 2368–2400. <https://doi.org/10.1161/STR.0000000000000070>
- Thornton, J., Bashir, Q., Aletich, V. A., Debrun, G. M., Ausman, J. I., & Charbel, F. T. (2000). What percentage of surgically clipped intracranial aneurysms have residual necks? *Neurosurgery*, *46*(6), 1294–1300. <https://doi.org/10.1097/00006123-200006000-00003>
- Timsit, C., Soize, S., Benaissa, A., Portefaix, C., Gauvrit, J.-Y., & Pierot, L. (2016). Contrast-Enhanced and Time-of-Flight MRA at 3T Compared with DSA for the Follow-Up of Intracranial Aneurysms Treated with the WEB Device. *AJNR. American Journal of Neuroradiology*, *37*(9), 1684–1689. <https://doi.org/10.3174/ajnr.A4791>
- UCAS Japan Investigators, Morita, A., Kirino, T., Hashi, K., Aoki, N., Fukuhara, S., Hashimoto, N., Nakayama, T., Sakai, M., Teramoto, A., Tominari, S., & Yoshimoto, T. (2012). The natural course of unruptured cerebral aneurysms in a Japanese cohort. *The New England Journal of Medicine*, *366*(26), 2474–2482. <https://doi.org/10.1056/NEJMoa1113260>
- Unruptured Intracranial Aneurysms — Risk of Rupture and Risks of Surgical Intervention. (1998). *New England Journal of Medicine*, *339*(24), 1725–1733. <https://doi.org/10.1056/NEJM199812103392401>
- Vallee, J.-N., Aymard, A., Vicaut, E., Reis, M., & Merland, J.-J. (2003). Endovascular treatment of basilar tip aneurysms with Guglielmi detachable coils: predictors of immediate and long-term results with multivariate analysis 6-year experience. *Radiology*, *226*(3), 867–879. <https://doi.org/10.1148/radiol.2263011957>

- van der Bilt, I. A. C., Hasan, D., Vandertop, W. P., Wilde, A. A. M., Algra, A., Visser, F. C., & Rinkel, G. J. E. (2009). Impact of cardiac complications on outcome after aneurysmal subarachnoid hemorrhage: A meta-analysis. *Neurology*, *72*(7), 635–642. <https://doi.org/10.1212/01.wnl.0000342471.07290.07>
- van Donkelaar, C. E., Bakker, N. A., Birks, J., Veeger, N. J. G. M., Metzemaekers, J. D. M., Molyneux, A. J., Groen, R. J. M., & van Dijk, J. M. C. (2019). Prediction of Outcome After Aneurysmal Subarachnoid Hemorrhage. *Stroke*, *50*(4), 837–844. <https://doi.org/10.1161/STROKEAHA.118.023902>
- van Rooij, S. B. T., van Rooij, W. J., Sluzewski, M., & Peluso, J. P. (2019). The Woven EndoBridge (WEB) for recurrent aneurysms: Clinical and imaging results. *Interventional Neuroradiology*. <https://doi.org/10.1177/1591019918798806>
- van Rooij, S., Sprengers, M., Peluso, J., Daams, J., Verbaan, D., van Rooij, W., & Majoie, C. (2020). A systematic review and meta-analysis of Woven EndoBridge single layer for treatment of intracranial aneurysms. *Interventional Neuroradiology*, *26*(4), 455–460. <https://doi.org/10.1177/1591019920904421>
- van Rooij, S., van Rooij, W., Sluzewski, M., & Peluso, J. (2019). The Woven EndoBridge (WEB) for recurrent aneurysms: Clinical and imaging results. *Interventional Neuroradiology*, *25*(1), 21–26. <https://doi.org/10.1177/1591019918798806>
- Venkatraman, A., Khawaja, A. M., Gupta, S., Hardas, S., Deveikis, J. P., Harrigan, M. R., & Kumar, G. (2018). Intra-arterial vasodilators for vasospasm following aneurysmal subarachnoid hemorrhage: a meta-analysis. *Journal of NeuroInterventional Surgery*, *10*(4), 380–387. <https://doi.org/10.1136/neurintsurg-2017-013128>
- Vergouwen, M. D. I., Vermeulen, M., van Gijn, J., Rinkel, G. J. E., Wijndicks, E. F., Muizelaar, J. P., Mendelow, A. D., Juvela, S., Yonas, H., Terbrugge, K. G., Macdonald, R. L., Diringier, M. N., Broderick, J. P., Dreier, J. P., & Roos, Y. B. W. E. M. (2010). Definition of Delayed Cerebral Ischemia After Aneurysmal Subarachnoid Hemorrhage as an Outcome Event in Clinical Trials and Observational Studies. *Stroke*, *41*(10), 2391–2395. <https://doi.org/10.1161/STROKEAHA.110.589275>
- Veznedaroglu, E., Benitez, R. P., & Rosenwasser, R. H. (2004). Surgically Treated Aneurysms Previously Coiled: Lessons Learned. *Neurosurgery*, *54*(2), 300–305. <https://doi.org/10.1227/01.NEU.0000103223.90054.C2>
- Vilkki, J. S., Juvela, S., Siironen, J., Ilvonen, T., Varis, J., & Porras, M. (2004). Relationship of local infarctions to cognitive and psychosocial impairments after aneurysmal subarachnoid hemorrhage. *Neurosurgery*, *55*(4), 790–802; discussion 802–3. <https://doi.org/10.1227/01.neu.0000137629.17424.6d>
- Vlak, M. H. M., Rinkel, G. J. E., Greebe, P., & Algra, A. (2013). Independent risk factors for intracranial aneurysms and their joint effect: a case-control study. *Stroke*, *44*(4), 984–987. <https://doi.org/10.1161/STROKEAHA.111.000329>
- Vlak, M. H. M., Rinkel, G. J. E., Greebe, P., Johanna, J. G., & Algra, A. (2012). Trigger factors for rupture of intracranial aneurysms in relation to patient and aneurysm characteristics. *Journal of Neurology*, *259*(7), 1298–1302. <https://doi.org/10.1007/s00415-011-6341-1>
- Wartenberg, K. E., Schmidt, J. M., Claassen, J., Temes, R. E., Frontera, J. A., Ostapkovich, N., Parra, A., Connolly, E. S., & Mayer, S. A. (2006). Impact of medical complications on outcome after subarachnoid hemorrhage\*. *Critical Care Medicine*, *34*(3), 617–623. <https://doi.org/10.1097/01.CCM.0000201903.46435.35>
- Westerlaan, H. E., van Dijk, J. M. C., Jansen-van der Weide, M. C., de Groot, J. C., Groen, R. J. M., Mooij, J. J. A., & Oudkerk, M. (2011). Intracranial Aneurysms in Patients with Subarachnoid Hemorrhage: CT Angiography as a Primary Examination Tool for Diagnosis—Systematic Review and Meta-Analysis. *Radiology*, *258*(1), 134–145. <https://doi.org/10.1148/radiol.10092373>

- White, P. M., Wardlaw, J. M., & Easton, V. (2000). Can Noninvasive Imaging Accurately Depict Intracranial Aneurysms? A Systematic Review. *Radiology*, 217(2), 361–370. <https://doi.org/10.1148/radiology.217.2.r00nv06361>
- Wiebers, D. O. (2003). Unruptured intracranial aneurysms: natural history, clinical outcome, and risks of surgical and endovascular treatment. *The Lancet*, 362(9378), 103–110. [https://doi.org/10.1016/S0140-6736\(03\)13860-3](https://doi.org/10.1016/S0140-6736(03)13860-3)
- Willinsky, R. A., Taylor, S. M., terBrugge, K., Farb, R. I., Tomlinson, G., & Montanera, W. (2003). Neurologic Complications of Cerebral Angiography: Prospective Analysis of 2,899 Procedures and Review of the Literature. *Radiology*, 227(2), 522–528. <https://doi.org/10.1148/radiol.2272012071>
- Winkler, E. A., Yue, J. K., Deng, H., Raygor, K. P., Phelps, R. R. L., Rutledge, C., Lu, A. Y., Rodriguez Rubio, R., Burkhardt, J.-K., & Abla, A. A. (2019). National trends in cerebral bypass surgery in the United States, 2002–2014. *Neurosurgical Focus*, 46(2), E4. <https://doi.org/10.3171/2018.11.FOCUS18530>
- Xiang, S., Fan, F., Hu, P., Yang, K., Zhai, X., Geng, J., Ji, Z., Lu, J., & Zhang, H. (2021). The sensitivity and specificity of TOF-MRA compared with DSA in the follow-up of treated intracranial aneurysms. *Journal of NeuroInterventional Surgery*, 13(12), 1172–1179. <https://doi.org/10.1136/neurintsurg-2020-016788>
- Yan, Y., Zhu, D., Tang, H., & Huang, Q. (2018). Safety and Efficacy of Flow Diverter Treatment for Aneurysm in Small Cerebral Vessels: A Systematic Review and Meta-Analysis. *World Neurosurgery*, 115, 54–64. <https://doi.org/10.1016/j.wneu.2018.04.009>
- Yang, P., Zhao, K., Zhou, Y., Zhao, R., Zhang, L., Zhao, W., Hong, B., Xu, Y., Huang, Q., Krings, T., & Liu, J. (2015). Stent-assisted Coil Placement for the Treatment of 211 Acutely Ruptured Wide-necked Intracranial Aneurysms: A Single-Center 11-Year Experience. *Radiology*, 276(2), 545–552. <https://doi.org/10.1148/radiol.2015140974>
- Youssef, P. P., Dornbos III, D., Peterson, J., Sweid, A., Zakeri, A., Nimjee, S. M., Jabbour, P., & Arthur, A. S. (2021). Woven EndoBridge (WEB) device in the treatment of ruptured aneurysms. *Journal of NeuroInterventional Surgery*, 13(5), 443–446. <https://doi.org/10.1136/neurintsurg-2020-016405>
- Zaidi, H. A., Montoure, A., Elhadi, A., Nakaji, P., McDougall, C. G., Albuquerque, F. C., Spetzler, R. F., & Zabramski, J. M. (2015). Long-term Functional Outcomes and Predictors of Shunt-Dependent Hydrocephalus After Treatment of Ruptured Intracranial Aneurysms in the BRAT Trial. *Neurosurgery*, 76(5), 608–615. <https://doi.org/10.1227/NEU.0000000000000677>
- Zhang, Y., Wang, Y., Kao, E., Flórez-Valencia, L., & Courbebaisse, G. (2019). Towards optimal flow diverter porosity for the treatment of intracranial aneurysm. *Journal of Biomechanics*, 82, 20–27. <https://doi.org/10.1016/j.jbiomech.2018.10.002>
- Zhou, G., Su, M., Yin, Y.-L., & Li, M.-H. (2017). Complications associated with the use of flow-diverting devices for cerebral aneurysms: a systematic review and meta-analysis. *Neurosurgical Focus*, 42(6), E17. <https://doi.org/10.3171/2017.3.FOCUS16450>









**TURUN  
YLIOPISTO**  
UNIVERSITY  
OF TURKU

ISBN 978-951-29-8987-4 (PRINT)  
ISBN 978-951-29-8988-1 (PDF)  
ISSN 0355-9483 (Print)  
ISSN 2343-3213 (Online)